Printed and published by D.G. Tripathi, Edited by Dr. Ramnik Sood, M.D. (Path.) for and on behalf of Tulip Diagnostics Private Ltd., Gitanjali, Tulip Block, Dr. Antonio Do Rego Bagh, Alto Santacruz, Bambolim Complex Post Office, Goa - 403 202, INDIA. Fax: (0832) 2458544. E-mail: sales@tulipgroup.com Website: www.tulipgroup.com

VOLUME - IX
ISSUE - LIII
SEP / OCT 2012

The Crux

BIMONTHLY FORUM FOR THE LABORATARIANS

CONTENTS

Editorial

Chickenpox (or **chicken pox**) is a highly contagious illness caused by primary infection with varicella zoster virus (VZV). It usually starts with vesicular skin rash mainly on the body and head rather than at the periphery and becomes itchy, raw pockmarks, which mostly heal without scarring. On examination, the observer typically finds lesions at various stages of healing.

Chickenpox is an airborne disease spread easily through coughing or sneezing of ill individuals or through direct contact with secretions from the rash. A person with chickenpox is infectious one to two days before the rash appears. They remain contagious until all lesions have crusted over (this takes approximately six days). Immunocompromised patients are contagious during the entire period as new lesions keep appearing. Crusted lesions are not contagious

Chickenpox has been observed in other primates, including chimpanzees and gorillas.

Chickenpox is the subject of this issue's **"DISEASE DIAGNOSIS"** of the month. We have commenced articles on common viral disorders and continue this in future communiqués too. Simple, common diseases can have fatal consequences if overlooked!

A craze these days, almost everyone who can afford, is going in for estimation of their Vit D and Vit B_{12} levels. Why has it acquired such a huge importance suddenly? Well, the **"INTERPRETATION"** segment lays threadbare all related aspects for you. When is Vit D testing mandatory, what are the indications, what are the reference values. All information of use has been compressed and presented in two pages.

While we sincerely hope and recommend that no sample should ever leave the doors of the primary lab. However, highly sophisticated tests may have to be sent to tertiary laboratories for testing. The process is not all that simple. What has to be done and how, is discretely provided to you under the **"TROUBLE SHOOTING"** section of this issue.

All work and no play makes Jack a dull boy! WE don't forget that ever. Each issue comes with its very own **"BOUQUET"** of various hues and fragrances. Please flip a few pages to believe us.

TÜV ISO 9001

Tulip Group

PUBLISHED FOR THE TULIP GROUP CUSTOMERS

FOR PRIVATE CIRCULATION ONLY

DISEASE DIAGNOSIS

CHICKEN POX

Background

The varicella-zoster virus (VZV) is the etiologic agent of the clinical syndrome of chickenpox (varicella). Zoster, a different clinical entity, is caused by reactivation of VZV after primary infection. VZV is a double-stranded deoxyribonucleic acid virus included in the Alphaherpesvirinae subfamily. Chickenpox is usually acquired through inhalation of airborne respiratory droplets from an infected host. High viral titers are found in the characteristic vesicles of chickenpox; viral transmission may also occur through direct contact with these vesicles, though the risk of transmission is lower. Chickenpox is largely a childhood disease, with more than 90% of cases occurring in children younger than 10 years. The disease is benign in the healthy child, and increased morbidity occurs in adults and immunocompromised patients. Since the introduction of widespread pediatric immunization, the incidence of varicella has declined significantly. Chickenpox is usually diagnosed clinically on the basis of the characteristic rash and successive crops of lesions. These may be found in various developmental and healing stages in affected sites. Patient exposure to an infected contact within the incubation period of 10-21 days is an important diagnostic clue. The more complicated course in adults with chickenpox can be associated with a more widespread rash; prolonged fever; and an increased likelihood of complications, the most common being varicella pneumonia. VZV can be isolated on vesicular fluid cultures, which provides a definitive diagnosis. Direct immunofluorescence has excellent sensitivity. Oral acyclovir should be considered for healthy persons at increased risk of severe varicella infections. Valacyclovir and famciclovir are other agents used in treatment. Intravenous acyclovir therapy is recommended for patients who are immune-suppressed or immune-compromised. Varicella-zoster immune globulin (VZIG) is indicated for use in highly susceptible, VZV-exposed immunocompromised or immunosuppressed populations. A live attenuated varicella vaccine (Oka strain) was approved by the US Food and Drug Administration in 1995 for prophylactic use in healthy children and adults.

Etiology

Chickenpox is usually acquired by the inhalation of airborne respiratory droplets from a VZV-infected host. High viral titers are found in the characteristic vesicles of chickenpox; thus, viral transmission may also occur through direct contact with these vesicles.

Epidemiology

Chickenpox is a common disease, with most cases occurring in the pediatric population. Varicella has neither a racial nor a sexual predilection.

International statistics

Countries with tropical and semitropical climates have a higher incidence of adult chickenpox than do countries with a temperate climate (eg, United States, Europe).

Pathophysiology

Chickenpox is usually acquired by the inhalation of airborne respiratory droplets from an infected host. The highly contagious nature of varicella-zoster virus (VZV) underlies the epidemics that spread quickly through schools. High viral titers are found in the characteristic vesicles of chickenpox; thus, despite the lower associated risk, viral transmission may also occur through direct contact with these vesicles. After initial inhalation of contaminated respiratory droplets, the virus infects the conjunctivae or the mucosae of the upper respiratory tract. Viral proliferation occurs in regional lymph nodes of the upper respiratory tract 2-4 days after initial infection; this is followed by primary viremia on postinfection days 4-6. A second round of viral replication occurs in the body's internal organs, most notably the liver and the spleen, followed by a secondary viremia 14-16 days post infection. This secondary viremia is characterized by diffuse viral invasion of capillary endothelial cells and the epidermis. VZV infection of cells of the malpighian layer produces both intercellular edema and intracellular edema, resulting in the characteristic vesicle. Exposure to VZV in a healthy child initiates the production of host immunoglobulin G (IgG), immunoglobulin M (IgM), and immunoglobulin A (IgA) antibodies; IgG antibodies persist for life and confer immunity. Cell-mediated immune responses are also important in limiting the scope and the duration of primary varicella infection. After primary infection, VZV is hypothesized to spread from mucosal and epidermal lesions to local sensory nerves. VZV then remains latent in the dorsal ganglion cells of the sensory nerves. Reactivation of VZV results in the clinically distinct syndrome of herpes zoster (shingles).

History

Chickenpox is usually diagnosed clinically on the basis of the characteristic rash and successive crops of lesions. Lesions may be found in all stages of development and healing in affected sites. A history of exposure to an infected contact within the incubation period of 10-21 days is also an important clue in the diagnosis. Childhood chickenpox is usually not heralded by a prodrome; it begins with the onset of an exanthem. In adults and adolescents, chickenpox may be preceded by a prodrome of nausea, myalgia, anorexia, and headache. The triad of rash, malaise, and a low-grade fever can signal disease onset, though the typical patient is infectious for 1-2 days prior to the development of rash. Small, erythematous macules appear on the scalp, face, trunk, and proximal limbs, with rapid sequential progression over 12-14 hours to papules, clear vesicles, and pustules and subsequent central umbilication and crust formation. Vesicles may appear on the palms and the soles and on the mucous membranes, together with painful, shallow, oropharyngeal or urogenital ulcers. Intense pruritus commonly accompanies the vesicular stage of the rash. The typical patient remains infectious for 4-5 days after the rash develops, by which time the last crop of vesicles has usually crusted over.

Secondary bacterial infection

Secondary bacterial infection of skin lesions, manifesting as impetigo, cellulitis, and erysipelas, is the most frequent complication in otherwise healthy children. Staphylococci and streptococci are the most commonly implicated bacterial pathogens. Bacterial superinfection may predispose to scarring. Localized bacterial superinfection rarely may manifest as septicemia, culminating in secondary bacterial pneumonia, otitis media, or necrotizing fasciitis. The latter represents significant, potentially life-threatening morbidity.

Disseminated primary varicella infection

Disseminated primary varicella infection, usually seen in the immunocompromised or adult populations, may have high morbidity. Ninety percent of cases of varicella pneumonia occur in the adult population. Rarer complications of disseminated chickenpox include myocarditis, gangrene, hepatitis, and glomerulonephritis.

CNS complications

Central nervous system complications of primary VZV infection may

occur, albeit very rarely. Reye syndrome, Guillain-Barré syndrome, acute cerebellar ataxia, and encephalitis have all been documented to occur after VZV infection.

Hemorrhagic complications

Thrombocytopenia and purpura secondary to VZV infection have been described in more than 100 patients. Hemorrhagic complications are more common in the immunocompromised or immunosuppressed populations, although healthy children and adults have been affected.

Five major clinical syndromes have been described: Febrile purpura, Malignant chickenpox with purpura, Postinfectious purpura, Purpura fulminans, Anaphylactoid purpura. These syndromes have variable courses, with febrile purpura being the most benign and having an uncomplicated outcome. In contrast, malignant chickenpox with purpura is a grave clinical condition that has a mortality exceeding 70%. The etiology of these hemorrhagic chickenpox syndromes is not known, although an autoimmune pathophysiologic mechanism has been implicated.

In utero VZV infection

In utero infection with VZV is a concern. Primary maternal chickenpox during pregnancy may produce latency of VZV in the dorsal root ganglia of the fetus. These children may remain asymptomatic, or they may develop zoster at a young age without a previous history of primary chickenpox infection. Primary maternal chickenpox infection in early to mid-pregnancy is estimated to have a 1-2% risk of causing the congenital varicella syndrome, which is characterized by limb hypoplasia, muscular atrophy, skin scarring, cortical atrophy, microcephaly, cataract formation, and rudimentary digits. Prepartum infection with onset of chickenpox in the mother 5 or more days previous to delivery allows transplacental passage of sufficient maternal IgG antibody to protect the newborn from severe, disseminated varicella infection. Peripartum infection of the fetus before sufficient maternal antibody has crossed the placenta to confer transient passive immunity to the fetus (ie, when the mother experiences onset of chickenpox < 5 d before delivery or within 2 d after delivery) often results in severe disseminated varicella in the newborn infant, which has substantial mortality.

Physical Examination

The characteristic chickenpox vesicle, surrounded by an erythematous halo, is described as a dewdrop on a rose petal (see the images below).

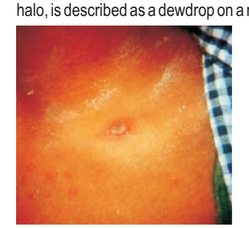

Dewdrop on rose petal characteristic vesicle of chickenpox

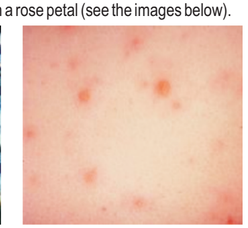

Vesicular eruption on the trunk demonstrating papules, vesicles, and crusts.

Chickenpox is clinically characterized by the presence of active and healing lesions in all stages of development within affected locations. Lesions characteristically heal without scarring, although excoriation or secondary bacterial superinfection predisposes to scar formation. Adults with chickenpox have a more complicated course than that occurring in children. Adults may experience a more widespread rash; prolonged fever; and an increased likelihood of complications, the most common being varicella pneumonia. Clinical variants of chickenpox infection also occur. Hemorrhagic lesions are rare and are most commonly associated with patients who are immunocompromised or immunosuppressed. Bullous chickenpox is a rare variant in which bullae appear instead of the characteristic vesicles. The possibility of bullous impetigo from *Staphylococcus aureus* must be addressed, especially in a child with persistent fever or relapse after he or she appeared to be improving. Bullous chickenpox may affect both children and adults and must be differentiated from other bullous disorders (eg, bullous pemphigoid, pemphigus). The course of the disease is believed to be unchanged, although a delay in diagnosis and treatment of elderly patients and immunocompromised patients may lead to serious morbidity. Chickenpox and other viral exanthems may appear concentrated in areas where intense sun exposure occurred during the incubation period. Patients with atopic dermatitis may show an atypical distribution of varicella, in which the characteristic eruption is primarily found on lichenified areas.

Diagnostic Considerations: Diagnostic considerations in cases of suspected chickenpox include viral exanthems, pityriasis lichenoides et varioliformis acuta, disseminated herpes simplex virus infection, atypical herpes zoster, rickettsial disease, and neonatal syphilis. All of the differential diagnoses listed are active considerations, with the exception of smallpox, which would be a concern in the event of biologic warfare.

Differential Diagnosis: Bullous Pemphigoid, Dermatitis Herpetiformis, Drug Eruptions, Erythema Multiforme, Herpes Simplex, Impetigo, Insect Bites, Smallpox, Syphilis.

Approach Considerations

The workup for chickenpox includes a Tzanck smear, vesicular fluid culture, serologic testing, chest radiography, and histologic examination.

Tzanck Smear

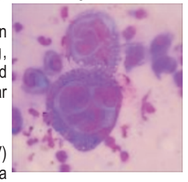

A Tzanck smear of vesicular fluid, which can be prepared in an office setting, demonstrates multinucleated giant cells and epithelial cells with eosinophilic intranuclear inclusion bodies.

Culture

Isolation of the varicella-zoster virus (VZV) through culture of vesicular fluid provides a definitive diagnosis; however, culturing for VZV is technically difficult, and cultures are positive less than 40% of the time. Direct immunofluorescence study offers excellent sensitivity and is more rapid than tissue culture. Polymerase chain reaction-based techniques are highly sensitive in identifying VZV, but they are not readily available.

Serology

Serologic evidence of immunity (native immunoglobulin G formation) to VZV can be achieved through a number of different assays, including the following: Enzyme immunoassay, Indirect fluorescent antibody, Complement fixation, Fluorescent antibody to membrane assay, Latex agglutination test. Enzyme immunoassay, fluorescent antibody to membrane assay, and indirect fluorescence are not widely available, and complement fixation is not highly sensitive for VZV. The latex agglutination test is the most popular serologic assay for determining exposure and immunity to VZV.

Chest Radiography: Chest radiography is indicated for adults who are experiencing pulmonary symptoms of chicken pox

Histologic Findings: Histologic examination of skin lesions does not differentiate VZV from herpes simplex virus (HSV) infection. Intranuclear eosinophilic inclusion bodies are seen in epithelial cells in both

infections. Leukocytoclastic vasculitis and hemorrhage are more common in VZV lesions than HSV.

Approach Considerations

Primary varicella infection in the healthy child is a rather benign disease that requires symptomatic therapy only. Oral acyclovir should be considered for healthy persons at increased risk of severe varicella infections. Adults and immunocompromised persons with chickenpox have a more complicated course than that occurring in children, and therefore, the condition necessitates a more aggressive pharmacotherapeutic approach. Intravenous acyclovir therapy is recommended for patients who are immunosuppressed or immunocompromised. Varicella-zoster immune globulin (VZIG) is indicated for use in highly susceptible, VZV-exposed immunocompromised or immunosuppressed populations. A live attenuated varicella vaccine (Oka strain) was approved by the FDA in 1995 for prophylactic use in healthy children and adults.

Treatment in Healthy Children

The symptoms of chickenpox in the pediatric population can be treated topically and with oral agents. Pruritus can be treated with calamine lotion or pramoxine gel; powdered oatmeal baths; or oral antihistamines. The nucleoside analogue acyclovir (20 mg/kg PO qid for 5 d), though shown to decrease the symptoms and duration of primary varicella infection when administered within 24 hours of onset of symptoms, is not commonly prescribed for otherwise healthy children. Given the high risk of varicella-related complications, children should be treated if any of the following conditions are a medical concern: Defects in cell-mediated immunity, Chronic atopic dermatitis, Chronic asthma, Iatrogenic immunosuppression, Long-term systemic steroid use, Splenic dysfunction, Nephrotic syndrome.

Treatment in Immunocompetent Adults

Oral acyclovir should be considered for healthy persons at increased risk of severe varicella infections, most notably patients older than 12 years. Oral acyclovir therapy in this population (800 mg 5 times/d for 7 d), begun within 24 hours of onset of symptoms, has been shown to decrease the duration of lesions and pyrexia, while reducing other symptoms and disease duration. Valacyclovir, the L-valyl ester of acyclovir, is a prodrug that has higher oral bioavailability than acyclovir. Valacyclovir is used in the treatment of herpes zoster, but no large-based clinical trials yet have demonstrated its efficacy in primary varicella infection of healthy, immunocompetent individuals. Famciclovir is a prodrug of penciclovir, which is a nucleoside analogue similar to acyclovir. Like valacyclovir, famciclovir has demonstrated efficacy in the treatment of herpes zoster, but it has not been extensively studied for use in primary varicella infection of healthy populations. A few case reports also have found sorivudine, a nucleoside analogue that is a potent in vivo inhibitor of varicella-zoster virus (VZV) replication, to be effective in the treatment of primary varicella in healthy adults. Larger scale clinical trials are needed to demonstrate the efficacy of this medication.

Treatment in the Immunocompromised or Immunosuppressed

Intravenous acyclovir therapy is recommended for patients who are immunosuppressed or immunocompromised, because of the life-threatening complications of primary varicella infection to which they are particularly susceptible. Severe disseminated disease, with the development of varicella pneumonia, encephalitis, hepatitis, and hemorrhagic complications, is much more common in this population than in other populations. Secondary complications (eg, bacterial pneumonia, meningitis) caused by bacterial superinfection of cutaneous lesions with subsequent septicemia, are also more common and dangerous among those who are immunocompromised. Case reports have described vidarabine, a purine nucleoside analogue, and interferon-alpha to be effective in the treatment of primary varicella infection of immunocompromised hosts. Acyclovir-resistant strains of VZV have been reported in patients with AIDS. Foscarnet, an inorganic pyrophosphate analogue that acts as a selective inhibitor of viral deoxyribonucleic acid polymerases and reverse transcriptases, is a potentially efficacious drug in patients with acyclovir-resistant VZV strains. Optimal dosage, duration of therapy, and efficacy in primary varicella infection need further investigation. Treatment of primary varicella in these populations is difficult and necessitates an integrated team approach. Continuing research into new antiviral agents and ongoing clinical trials are constantly adding new information relative to the pharmacotherapeutic options in the fight against VZV infections.

Prognosis

Chickenpox that affects a healthy child is usually a self-limited disease. Increased morbidity occurs in adult and immunocompromised populations.

Patient Education

Parents of infected children should be instructed to trim their children's fingernails to minimize skin damage from scratching and the associated complications of bacterial superinfection. Also, it is important to advise parents not to use aspirin for fever control, because the development of Reye syndrome is associated with salicylate administration in children with chickenpox.

Passive Immunization

Varicella-zoster immune globulin (VZIG), a human immunoglobulin preparation, is indicated for use in highly susceptible, VZV-exposed immunocompromised or immunosuppressed populations. These populations would comprise, for example, patients who have undergone bone marrow transplantation, those with leukemia, patients with congenital or acquired immunodeficiency syndromes, patients undergoing immunosuppressive therapy for transplant procedures, and infants born to mothers who experience onset of chickenpox within 5 days prior to delivery or within 2 days after delivery. VZIG given within 96 hours of exposure can modify the course of disease but does not prevent it. Maximal effectiveness is seen with administration as soon as possible after exposure.

Varicella-Zoster Virus Vaccination: A live attenuated varicella vaccine (Oka strain) was approved by the US Food and Drug Administration in 1995 for prophylactic use in healthy children and adults. Vaccination recommendations consist of 1 dose for healthy children aged 12-18 months and 2 doses, in a 4- to 8-week interval, in susceptible persons older than 13 years. Studies in Japan point to high seroconversion rates and long-term immunity in children after vaccination. The need for revaccination, or a booster immunization, will be addressed after more long-term studies have been completed. The effectiveness of the vaccine wanes over time, ranging from 97% in the first year after vaccination to 84% at 8 years post vaccination. Breakthrough varicella, which is seen in previously immunized persons, is a well-known clinical entity. The disease course is much milder than conventional primary varicella and is characterized by an atypical clinical presentation in which only a few papules or papulovesicles are present. Transmission of VZV to other individuals may occur, although at lower rates than in nonimmunized people with primary varicella. Adverse effects of the vaccination include pain and erythema at the site of injection, allergic reactions to gelatin, and the development of a localized chickenpox. Vaccine-induced herpes zoster infection in immunocompetent and immunocompromised populations has also been reported, though it is a rare phenomenon. Rarer still is the transmission of vaccine-associated virus from vaccinated individuals to susceptible contacts.

INTERPRETATION

Vitamin D

Vitamin D is a group of fat-soluble secosteroids. In humans, vitamin D is unique both because it functions as a prohormone and because the body can synthesize it (as vitamin D_3) when sun exposure is adequate (hence its nickname, the "sunshine vitamin"). Although vitamin D is commonly called a vitamin, it is not in the sense an essential dietary vitamin as it can be synthesized in adequate amounts by all mammals from sunlight. Vitamin D fits within the definition of vitamin as it is "an organic compound required as a vital nutrient in tiny amounts by an organism. In other words, an organic chemical compound (or related set of compounds) is called a vitamin when it cannot be synthesized in sufficient quantities by an organism, and must be obtained from the diet". As with other compounds called vitamins, it was discovered in an effort to find the dietary substance that was lacking in a disease, namely, rickets, the childhood form of osteomalacia.. Additionally, like other compounds called vitamins, in the developed world vitamin D is added to staple foods, such as milk, to avoid disease due to deficiency. Measures of serum levels (from a vitamin D_3 blood test) reflect endogenous synthesis from exposure to sunlight as well as intake from the diet, and it is believed that synthesis may contribute generally to the maintenance of adequate serum concentrations. The evidence indicates that the synthesis of vitamin D from sun exposure works in a feedback loop that prevents toxicity but, because of uncertainty about the cancer risk from sunlight, no recommendations are issued by the Institute of Medicine, USA, for the amount of sun exposure required to meet vitamin D requirements. Accordingly, the Dietary Reference Intakes for vitamin D assume that no synthesis occurs and that all of a person's vitamin D is from their diet, although that will rarely occur in practice. Vitamin D is converted to calcidiol in the liver. Part of the calcidiol is converted by the kidneys to calcitriol, the biologically-active form of vitamin D. This circulates as a hormone in the blood, regulating the concentration of calcium and phosphate in the bloodstream and promoting the healthy growth and remodeling of bone. Calcidiol is also converted to calcitriol outside of the kidneys for other purposes, such as the proliferation, differentiation and apoptosis of cells; calcitriol also affects neuromuscular function and inflammation. Vitamin D has a key role in bone health. Supplements of vitamin D have not been found to improve other health outcomes. The best evidence of benefit is for bone health

Health effects of vitamin D supplements

Current evidence supports a positive role for vitamin D in bone health, but not in other health conditions. Emerging evidence suggests that vitamin D may be harmful at levels which can be reached through the use of supplements.

Mortality: In general supplements of vitamin D do not decrease mortality. For elderly women in dependent care there is some evidence for a reduction in mortality. Excess or deficiency levels of vitamin D appear to cause abnormal functioning and premature aging with a U-shaped risk curve between serum 25OHD level and all-cause mortality.

Bone health: As mentioned above, vitamin D deficiency definitely causes osteomalacia (called rickets when it occurs in children). Beyond that, low serum vitamin D levels have been associated with falls, and low bone mineral density. Supplementation with vitamin D and calcium improves bone mineral density slightly, as well as decreases the risk of falls and fractures in certain groups of people.

Cardiovascular disease: Evidence for health effects from vitamin D supplementation for cardiovascular health is poor. Moderate to high doses may reduce cardiovascular disease risk but are of questionable clinical significance. There is a suggestion that vitamin D deficiency can be associated with heart palpitations, perhaps because of its regulation of magnesium and calcium .

Asthma: Lower vitamin D serum levels were associated with corticosteroid use and worsening airflow limitation in one study of asthmatic patients. Vitamin D enhanced glucocorticoid action in immune markers called peripheral blood mononuclear cells (PBMCs) from asthmatic patients and enhanced the immunosuppressive function of the steroid, dexamethasone, in vitro.

Cancer: Low vitamin D levels are associated with some cancers. Clinical benefits are inconclusive vis-à-vis cancers.

Multiple sclerosis: Vitamin D deficiency may have a role in multiple sclerosis. "The reasons why vitamin D deficiency is thought to be a risk factor for MS are as follows: (1) MS frequency increases with increasing latitude, which is strongly inversely correlated with duration and intensity of UVB from sunlight and vitamin D concentrations; (2) prevalence of MS is lower than expected at high latitudes in populations with high consumption of vitamin-D-rich fatty fish; and (3) MS risk seems to decrease with migration from high to low latitudes. It is not known whether interventions to increase levels of vitamin D in a person can actually treat or prevent MS.

Infections: Vitamin D appears to have effects on immune function. It has been postulated to play a role in influenza with lack of vitamin D synthesis during the winter as one explanation for high rates of influenza infection during the winter. As of 2012 it is being investigated in controlled clinical trials. Vitamin D may also play a role in HIV.

Neurodegenerative disease: As basic research has found that vitamin D may regulate "processes known to go awry in Parkinson's disease and other neurodegenerative disorders, including neurotrophin, inducible nitric oxide synthase, glutathione and monoamine synthesis, and apoptosis", studies have been conducted to see if patients with Parkinson's or Alzheimer's disease are deficient in vitamin D. Clinical trials are being conducted to determine if vitamin D supplementation can treat or prevent Parkinson's disease.

Hair Health: Adequate vitamin D may also be associated with healthy hair follicle growth cycles.

Deficiency

Hypovitaminosis D: A diet deficient in vitamin D causes osteomalacia (called rickets when it occurs in children), which is a softening of the bones. In the developed world, this is a rare disease. Low blood calcidiol (25-hydroxy-vitamin D) can result from avoiding the sun. Deficiency results in impaired bone mineralization, and leads to bone softening diseases including: Rickets, a childhood disease characterized by impeded growth and deformity of the long bones, can be caused by calcium or phosphorus deficiency as well as a lack of vitamin D; today it is largely found in low income countries in Africa, Asia or the Middle East and in those with genetic disorders such as pseudovitamin D deficiency rickets. Osteomalacia, a bone-thinning disorder that occurs exclusively in adults, is characterized by proximal muscle weakness and bone fragility. The effects of osteomalacia are thought to contribute to chronic musculoskeletal pain, there is no persuasive evidence of lower vitamin D status in chronic pain sufferers.

Toxicity

Hypervitaminosis D: In healthy adults, sustained intake of more than 1250 micrograms/day (50,000 IU) can produce overt toxicity after several months; those with certain medical conditions such as primary hyperparathyroidism are far more sensitive to vitamin D and develop hypercalcemia in response to any increase in vitamin D nutrition, while maternal hypercalcemia during pregnancy may increase fetal sensitivity to effects of vitamin D and lead to a syndrome of mental retardation and facial deformities. Pregnant or breastfeeding women should consult a doctor before taking a vitamin D supplement. For infants (birth to 12 months), the tolerable upper limit (maximum amount that can be tolerated without harm) is set at 25 micrograms/day (1000 IU). One thousand micrograms (40,000 IU) per day in infants has produced toxicity within one month. Vitamin D overdose causes hypercalcemia, and the main symptoms of vitamin D overdose are those of hypercalcemia: anorexia, nausea, and vomiting can occur, frequently followed by polyuria, polydipsia, weakness, nervousness, pruritus, and, ultimately, renal failure. Proteinuria, urinary casts, azotemia, and metastatic calcification(especially in the kidneys) may develop. Vitamin D toxicity is treated by discontinuing vitamin D supplementation and restricting calcium intake. Kidney damage may be irreversible. Exposure to sunlight for extended

periods of time does not normally cause vitamin D toxicity. Within about 20 minutes of ultraviolet exposure in light-skinned individuals (3–6 times longer for pigmented skin), the concentrations of vitamin D precursors produced in the skin reach an equilibrium, and any further vitamin D that is produced is degraded.

Forms

Several forms (vitamers) of vitamin D exist. The two major forms are vitamin D_2 or ergocalciferol, and vitamin D_3 or cholecalciferol, vitamin D without a subscript refers to either D_2 or D_3 or both. These are known collectively as calciferol.

Recommendations

Dietary reference intakes: Different institutions propose different recommendations concerning daily amounts of the vitamin : Commonly recommended daily intake of vitamin D is not sufficient if sunlight exposure is limited. (Conversion : 1 µg = 40 IU and 0.025 µg = 1 IU.)

By and large the following regime can be followed: The most commonly recommended dietary allowances (RDA) for vitamin D are:

0–12 months	:	400 IU/day (10 µg/day)
1–70 years of age	:	600 IU/day (15 µg/day)
71+ years of age	:	800 IU/day (20 µg/day)
Pregnant/lactating	:	600 IU/day (15 µg/day)

Dietary sources

Vitamin D_2: *Ergocalciferol:* Plantae, alfalafa, various forms of Fungi are good sources of this form. Vitamin D_2, or ergocalciferol found in fungi, is synthesized from viosterol, which in turn is activated when ultraviolet light stimulates ergosterol. Human bioavailability of vitamin D_2 from vitamin D_2-enhanced button mushrooms via UV-B irradiation is effective in improving vitamin D status and not different to a vitamin D_2 supplement. Vitamin D_2 from UV-irradiated yeast baked into bread is bioavailable. By visual assessment or using a chromometer, no significant discoloration of irradiated mushrooms, as measured by the degree of "whiteness", was observed. Claims have been made that a normal serving (approx. 3 oz or 1/2 cup, or 60 grams) of fresh mushrooms treated with ultraviolet light have increased vitamin D content to levels up to 80 micrograms, or 2700 IU if exposed to just 5 minutes of UV light after being harvested.

Vitamin D_3: *Cholecalciferol:* In some countries, staple foods are artificially fortified with vitamin D. Dietary sources of vitamin D include: Fatty fish, whole egg, beef liver and fish liver oils are good sources of naturally occuring this form of Vitamin D.

Vitamin D testing is recommended for the following disorders and diseases: Cardiovascular disease including stroke & hypertension, Cancer, especially prostate, Osteoporosis/osteomalacia, Low blood calcium levels, Chronic bone/muscle/joint pain, Periodontal disease, Diabetes type I & II, Inflammatory bowel diseases, Rheumatoid arthritis, Other autoimmune diseases (multiple sclerosis), Chronic fatigue, Depression & mood disorders, Schizophrenia, Cognitive impairment in seniors, Birth defects.

Indications For Vitamin D Testing: Patients diagnosed with any of the Vitamin D related diseases (cancer, diabetes, hypertension, heart disease, multiple sclerosis, systemic lupus erythematosus, depression, Alzheimer's, Parkinson's, epilepsy, and other others). Patients with osteoporosis or rickets. Persistent and nonspecific musculoskeletal pain. Signs of depression or lack of energy. Patients with gastrointestinal disease and/or who have had a cholecystectomy. Elderly individuals. Overweight individuals with a BMI >25. Infants that are exclusively breastfed or children without a well-balanced diet. Individuals taking Vitamin D supplementation greater than 50 mcg (2,000 IUs) per day. Individuals that reside above 42 degrees north latitude. Individuals with medium to dark complexions or who do not regularly receive 20 minutes of direct sunlight each day.

BOUQUET

In Lighter Vein

In Ireland there is a mental institution that every year picks two of its most reformed patients and questions them. If they get the questions right they are free to leave. This year the two lucky gents were Patty and Mike. They were called down to the office and left there by the orderly. They were told to wait as the doctor got their files. The doctor came out and motioned for Patty to come in for his questioning. When Patty came into the office he was instructed to sit in the seat across from the doctor.

"Patty you know the tradition of this institution so I imagine you know why you are here. You will be asked two questions, and if you get them right, you will be free to go. Do you understand all that you have been told?" said the doctor with a rather sly grin.

Patty nodded and the doctor began to question him. The first question was this. "Patty if I was to poke out one of your eyes what would happen?"

"I would be half blind of course," Patty answered without much thought.

"What would happen if I poked out the other eye?"

"I would be completely blind," said Patty knowing that he had just gotten his freedom. The doctor then sent him outside while he drew up the paperwork and accessed Mike's files.

When Patty got into the waiting room however, he told Mike what the questions would be and what the correct answers were. The doctor calls in Mike and he followed the same procedure that he had with Patty. "Mike the first question is what would happen if I cut off your ear?"

"I would be blind in one eye," he said remembering what he had been told. This received a perplexed look from the doctor but he just simply asks the other question so that he could figure out what the man was thinking. "Mike, what would happen if I cut off your other ear?"

"I would be completely blind," he answered with a smile as if he knew he had passed. But then the doctor asked him what his reasoning was, and he said flatly, "Me hat would fall down over me eyes."

Wisdom Whispers

- What Is More Painful? When A Person Whom You Trust Hurts You Or The Person Whom You Hurt...Still Trusts You? Think.....!
- Somebody Asked GOD 'I Want Peace" GOD Replied, "Remove The I, That Is Ego; remove The Want, That Is Desire; and Peace Will Be Automatically There.
- If You like someone, Show it. It will be sweeter than Telling. But If You don't like someone, Just Tell it. It will be less painful than Showing it.
- Don't Guess A Person's Character On His Present Situation Coz Time Has The Power To Change An Ordinary Coal Into A Precious Diamond.
- Crying doesn't help. It only tells the enemy where you are.
- "There are two kinds of people in this world, those who divide the world into two kinds of people and those who don't".
- Nature is so bountiful..we waste so much time in concrete maze.
- Faster hardware doesn't solve business problems – unless the business problem is slow hardware.
- A city is a large community where people are lonesome together.
- I've been doing a lot of abstract painting lately, extremely abstract. No brush, no paint, no canvas, I just think about it.

Brain Teasers

Identify the species of the malarial parasites by looking at the images of their micro-gametocytes

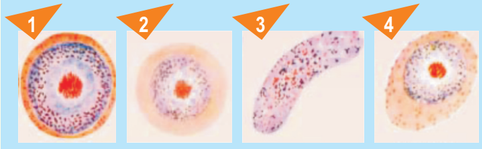

Answers: 1. P. vivax 2. P. malariae 3. P. falciparum 4. P. ovale

TROUBLESHOOTING

BLOOD SAMPLES TRANSPORTATION

This protocol is for human clinical blood specimens collected for analysis and to be transported. Collect specimens and package them for shipment as described below unless otherwise directed.

REQUIRED SPECIMENS

Collect the specimens defined below. Blood should be collected only by trained personnel using aseptic methods and working under the direction of a qualified, licensed practitioner. Standard venipuncture blood collection and handling procedures (CLSI Guideline H3 and H18) should be followed.

SPECIMEN COLLECTION

Collect a whole blood specimen into the type of blood tube as directed. The tube will be one of those listed below. Collect the specimen by full-draw, vacuum-fill only (**unopened**) directly into the blood tube. Do not collect by a syringe draw and transfer. Plastic (PET) tubes are preferred. Lavender-top (EDTA) tube. Mix by inverting 8-10 times. Gray-top (oxalate/fluoride) tube. Mix by inverting 8-10 times. Green-top (heparin) tube. Mix by inverting 8-10 times.

EVIDENTIARY REQUIREMENTS

Apply evidence tape and the tape applicator's initials to each specimen container and secondary packaging as described below. **Evidence tape-** Place a single, unbroken strip of waterproof, tamper-evident forensic evidence tape on the container being careful not to cover the specimen ID label. Begin by sticking the tape to the specimen container at one side, somewhat below the top, then apply it over the top, and finally bring it down and stick it to the opposite side of the container. Also apply evidence tape to the blank containers. **Initialing -** The individual applying the evidence tape must write their initials in indelible ink on the tape and container so their initials are approximately ½ on the tape and ½ on the container. Apply tape to the secondary container and initial in the same manner. **Chain-of-custody -** A chain of custody form must be completed for the specimens. Chain of custody forms do not need to be transported with specimens. Each entity/organization handling the specimens is responsible for the specimens only during the time that they have control of the specimens. Each entity/organization receiving the specimens must sign-off on the chain of custody form of the entity/organization relinquishing the specimens to close that chain. When receiving specimens, each new entity/organization must begin their own chain of custody and have the entity/organization relinquishing the specimens sign their chain of custody to start the chain and indicate that they have transferred the specimens. When specimens are transferred between entities/organizations, each entity/organization retains their chain of custody forms. NOTE: When the individual relinquishing the specimens (relinquisher) and the individual receiving the specimens (receiver) are not together at the time of specimen transfer, the relinquisher will document on their chain of custody that the receiver is Courier Tracking Number or have the individual transporting the specimens sign the chain of custody to indicate that they have taken control of the specimens. Likewise, when the receiver receives the specimens, they will document on their chain of custody that the relinquisher is Courier Tracking Number or the have the individual transporting the specimens sign the chain of custody.

STORAGE REQUIREMENTS

Specimens must be refrigerated within 30 minutes of collection and maintained at refrigeration temperature (4°C) continuously. Do not freeze blood specimens. **BLANKS:** Tube blanks for measuring background contamination must be included with each shipment of specimens. For each lot number of tubes used for collection, please provide two (2) unopened tubes.

DOCUMENTATION AND LABELING

Label specimens with labels generated by your facility. Follow your facility's procedures for proper sample labeling. Do not include any personal identifiers on the specimen containers. Inclusion of the collector's initials, and date and time of collection will allow law enforcement officials to trace the specimen back to the collector should there be a need to have the collector testify as to the specimen collection. Maintain a list of names with corresponding sample identification numbers or bar codes at the collection site to enable results to be reported to the patients. Prepare an itemized shipping list for each secondary package.

PACKAGING SPECIMENS FOR TESTING

Follow all current regulations in the packaging and shipping of specimens. Pack and ship these samples as DIAGNOSTIC SPECIMENS. Packaging for diagnostic specimens requires triple packaging, consisting of a leak-proof primary receptacle (the tube), a leak-proof secondary packaging that meets 49CFR173.199(b), and an outer packaging. Use styrofoam-insulated corrugated fiberboard outer packaging containers. Specimens must be maintained at refrigeration temperature (4°C) during transportation. **Secondary packaging:** Primary receptacles must be packed in secondary packaging so they will not break, be punctured, or leak their contents into the secondary packaging under normal handling conditions. Fragile primary receptacles packaged together must be individually wrapped or separated so they are not in physical contact. If more than one type of blood tube specimen is collected package them into separate secondary containers. Separate each tube of blood collected from other tubes (e.g., using a gridded box or a foam rack) or wrap tubes to prevent contact between tubes. To facilitate processing upon receipt, package blood tubes so that similar tubes are packaged together (e.g., all purple-tops together) and not mixed (i.e., purple-tops and green/gray-tops in the same package) in the secondary packaging. Place absorbent material between the primary receptacle and the secondary packaging. Use enough absorbent material to absorb the entire contents of primary receptacles. Place tubes in secondary packages. A variety of secondary packages may be used, for example, a gridded box wrapped with absorbent material and sealed inside a rigid leak-proof container or a two-part system of a plastic bag and envelope. Secondary containers must be marked with a Biohazard warning label or be completely red in color. Wrap a single continuous piece of evidence tape around the secondary container and initial, in indelible ink, ½ on the tape and ½ on the packaging. **Outer packaging:** Use Styrofoam-insulated corrugated fiberboard containers. Outer packaging may not exceed a 4 L (1 gallon) capacity. Place additional absorbent material in the bottom of the outer container for cushioning and to absorb condensation from the cold packs. Add a layer of frozen cold packs. Do not use ice. Place secondary containers on top of the cold packs. Both purple-top and gray/green-top containing secondary packages may be packaged in the same outer packaging. Place additional cold packs or absorbent material between the secondary containers to reduce their movement within the outer container. Place a layer of frozen cold packs on top of the secondary containers. Place a complete, itemized list of contents (with sample identification numbers) in a plastic zippered bag on top of the secondary packaging before closing the Styrofoam lid. Place the completed chain-of-custody forms in a plastic zippered bag on top of the Styrofoam lid. Affix labels and markings on the top of the packaging to increase the probability the package will be kept in the upright position. Clearly label the package with "From" sender's address and "To" recipient's address. Ensure that two (2) upwards-pointing orientation arrows are located on two opposite sides of the outer container. Place a label on the outer container that indicates the proper name, "DIAGNOSTIC SPECIMENS" adjacent to the shipper's address that appears on the package.

CRITERIA FOR SPECIMEN REJECTION

Specimens may be rejected if any of the following conditions are evident upon receipt: Specimen tube is broken or leaking. Specimen has warmed above 8°C. Primary receptacle not sealed with evidence tape. Evidence tape has been tampered with. Itemized list of specimens is not included.