VOLUME - X
ISSUE - LX
NOV / DEC 2013

The Crux

BIMONTHLY FORUM FOR THE LABORATORIANS

CONTENTS

Editorial

In medicine, inflammatory bowel disease (IBD) is a group of inflammatory conditions of the colon and small intestine. The major types of IBD are Crohn's disease and ulcerative colitis.

The main forms of IBD are Crohn's disease and ulcerative colitis (UC). Inflammatory bowel diseases are considered autoimmune diseases, in which the body's own immune system attacks elements of the digestive system.

Accounting for far fewer cases are other forms of IBD, which are not always classified as typical IBD: Collagenous colitis, Lymphocytic colitis, Ischaemic colitis, Diversion colitis, Behçet's disease, Indeterminate colitis.

The main difference between Crohn's disease and UC is the *location* and *nature* of the inflammatory changes. Crohn's can affect any part of the gastrointestinal tract, from mouth to anus (*skip lesions*), although a majority of the cases start in the terminal ileum. Ulcerative colitis, in contrast, is restricted to the colon and the rectum. Microscopically, ulcerative colitis is restricted to the mucosa (epithelial lining of the gut), while Crohn's disease affects the whole bowel wall ("transmural lesions").

Finally, Crohn's disease and ulcerative colitis present with extra-intestinal manifestations (such as liver problems, arthritis, skin manifestations and eye problems) in different proportions.

Rarely, a definitive diagnosis neither of Crohn's disease nor of ulcerative colitis can be made because of idiosyncrasies in the presentation. In this case, a diagnosis of indeterminate colitis may be made. Although a recognised definition, not all centres refer to this.

The “DISEASE DIAGNOSIS” segment of this issue delves deep into all clinico-diagnostic aspects of IBD.

It was but natural that we interpreted the various physical abnormalities of stool in this issue. So, “INTERPRETATION” portion does exactly that. Simple yet oft forgotten, it is spread out on paper for you in black and white.

Again falling in the realm of but natural, the “TROUBLESHOOTING” section outlines a much often requisitioned for investigation – namely – FOBT. All intricacies of performing this simple yet very important investigation are presented for your consumption.

And lastly “BOUQUET” with all its hues and fragrances has not been forgotten!

DISEASE DIAGNOSIS

INFLAMMATORY BOWEL DISEASE

Background

Inflammatory bowel disease (IBD) is an idiopathic disease caused by a dysregulated immune response to host intestinal microflora. The 2 major types of IBD are ulcerative colitis (UC), which is limited to the colon, and Crohn disease (CD), which can involve any segment of the gastrointestinal (GI) tract from the mouth to the anus, involves "skip lesions," and is transmural (see the images below). There is a genetic predisposition for IBD (see Etiology), and patients with this condition are more prone to the development of malignancy.

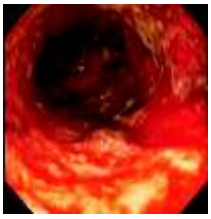

Severe colitis noted during colonoscopy in a patient with inflammatory bowel disease. The mucosa is grossly denuded, with active bleeding noted. The patient had her colon resected very shortly after this view was obtained.

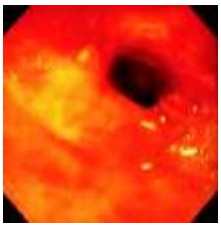

Stricture in the terminal ileum noted during colonoscopy in a patient with inflammatory bowel disease. This image depicts a narrowed segment visible upon intubation of the terminal ileum with the colonoscope. Relatively little active inflammation is present, indicating that this is a cicatrix stricture.

Ulcerative colitis and Crohn disease share many extraintestinal manifestations, although some of these tend to occur more commonly with either condition (see the image below). Eye-skin-mouth-joint extraintestinal manifestations (eg, oral aphthae, erythema nodosum, large-joint arthritis, and episcleritis) reflect active disease, whereas pyoderma gangrenosum, primary sclerosing cholangitis (PSC), ankylosing spondylitis, uveitis, kidney stones, and gallstones may occur in quiescent disease. Although both ulcerative colitis and Crohndisease havedistinct pathologic findings, approximately 10-15% of patients cannot be classified definitively into either type; in such patients, the disease is labeled as indeterminate colitis. Systemic symptoms are common in IBD and include fever, sweats, malaise, and arthralgias. The rectum is always involved in ulcerative colitis, and the disease primarily involves continuous lesions of the mucosa and the submucosa. Both ulcerative colitis and Crohn disease usually have waxing and waning intensity and severity. When the patient is symptomatic due to active inflammation, the disease is considered to be in an active stage (the patient is having a flare of the IBD). In many cases, symptoms correspond well to the degree of inflammation present for either disease, although this is not universally true. In some patients, objective evidence linking active disease to ongoing inflammation should be sought before administering medications with significant adverse effects, because patients with IBD can have other reasons for their gastrointestinal symptoms unrelated to their IBD, including coexisting irritable bowel syndrome (IBS), celiac disease, or other confounding diagnoses, such as nonsteroidal anti-inflammatory drug (NSAID) effects and ischemic or infectious colitis. Although ulcerative colitis and Crohn disease have significant differences, many, but not all, of the treatments available for one condition are also effective for the other. Surgical intervention for ulcerative colitis is curative for colonic disease and potential colonic malignancy, but it is not curative for Crohn disease. (See Treatment.)

Pathophysiology

The common end pathway of ulcerative colitis is inflammation of the mucosa of the intestinal tract, causing ulceration, edema, bleeding, and fluid and electrolyte loss. In several studies, genetic factors appeared to influence the risk of inflammatory bowel disease (IBD) by causing a disruption of epithelial barrier integrity, deficits in autophagy, deficiencies in innate pattern recognition receptors, and problems with lymphocyte differentiation, especially in Crohn disease. Inflammatory mediators have been identified in IBD, and considerable evidence suggests that these mediators play an important role in the pathologic and clinical characteristics of these disorders. Cytokines, which are released by macrophages in response to various antigenic stimuli, bind to different receptors and produce autocrine, paracrine, and endocrine effects. Cytokines differentiate lymphocytes into different types of T cells. Helper T cells, type 1 (Th-1), are associated principally with Crohn disease, whereas Th-2 cells are associated principally with ulcerative colitis. The immune response disrupts the intestinal mucosa and leads to a chronic inflammatory process. In animal studies, a local irritant (eg, acetic acid, trinitrobenzene sulfonic acid) can be inserted via an enema into the colon of rats or rabbits to induce a chemical colitis. An interleukin-10 (IL-10) knockout mouse has been genetically engineered to have some characteristics similar to those of a human with IBD. The cotton-top marmoset, a South American primate, develops a colitis very similar to ulcerative colitis when the animal is subjected to stress.

Ulcerative colitis: In ulcerative colitis, inflammation begins in the rectum and extends proximally in an uninterrupted fashion to the proximal colon and could eventually involve the entire length of the large intestine. The rectum is always involved in ulcerative colitis; and unlike in Crohn disease, there are no "skip areas" (ie, normal areas of the bowel interspersed with diseased areas), unless pretreated with typical rectal therapy (ie, a steroid or 5-aminosalicylic acid [5-ASA] enema). The disease remains confined to the rectum in approximately 25% of cases, and in the remainder of cases, ulcerative colitis spreads proximally and contiguously. Pancolitis occurs in 10% of patients. The distal terminal ileum may become inflamed in a superficial manner, referred to as backwash ileitis. Even with less than total colonic involvement, the disease is strikingly and uniformly continuous. As ulcerative colitis becomes chronic, the colon becomes a rigid foreshortened tube that lacks its usual haustral markings, leading to the lead-pipe appearance observed on barium enema. (See the images below.)

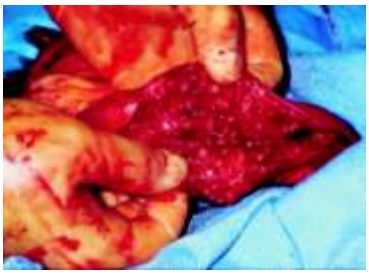

Inflamed colonic mucosa demonstrating pseudopolyps in a patient with ulcerative colitis.

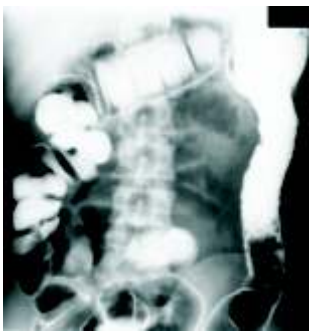

Double-contrast barium enema study shows pseudopolyposis of the descending colon in a patient with ulcerative colitis.

Crohn disease: Crohn disease can affect any portion of the gastrointestinal tract, from the mouth to the anus, and causes 3 patterns of involvement: inflammatory disease, strictures, and fistulas. This disease consists of segmental involvement by a nonspecific granulomatous inflammatory process. The most important pathologic

feature of Crohn disease is that it is transmural, involving all layers of the bowel, not just the mucosa and the submucosa, which is characteristic of ulcerative colitis. Furthermore, Crohn disease is discontinuous, with skip areas interspersed between 2 or more involved areas. Late in the disease, the mucosa develops a cobblestone appearance, which results from deep, longitudinal ulcerations interlaced with intervening normal mucosa (see the images below). In 35% of cases, Crohn disease occurs in the ileum and colon; in 32%, solely in the colon; in 28%, in the small bowel; and in 5%, in the gastroduodenal region. Diarrhea, cramping, and abdominal pain are common symptoms of Crohn disease in all of the above locations, except for the gastroduodenal region, in which anorexia, nausea, and vomiting are more common. Rectal sparing is a typical but not constant feature of Crohn disease. However, anorectal complications (eg, fistulas, abscesses) are common. Much less commonly, Crohn disease involves the more proximal parts of the GI tract, including the mouth, tongue, esophagus, stomach, and duodenum.

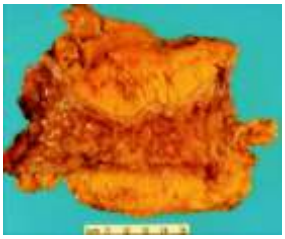

Cobblestone change of the mucosa of the terminal ileum in a patient with Crohn disease. Communicating fissures and crevices in the mucosa separate islands of more intact, edematous epithelium.

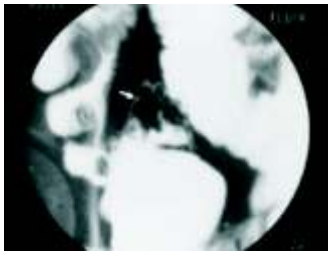

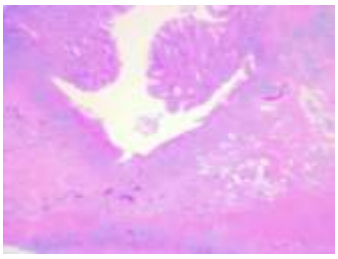

This computed tomography scan from a patient with terminal ileal Crohn disease shows an enteroenteral fistula (arrow) between loops of diseased small intestine. Deep, fissuring ulcer in a patient with Crohn disease. Note the increase in submucosal inflammation and scattered lymphoid aggregates.

Cholelithiasis and nephrolithiasis: The incidence of gallstones and kidney stones is increased in Crohn disease because of malabsorption of fat and bile salts. Gallstones are formed because of increased cholesterol concentration in the bile, which is caused by a reduced bile salt pool. Patients who have Crohn disease with ileal disease or resection are also likely to form calcium oxalate kidney stones. With the fat malabsorption, unabsorbed long-chain fatty acids bind calcium in the lumen. Oxalate in the lumen is normally bound to calcium. Calcium oxalate is poorly soluble and poorly absorbed; however, if calcium is bound to malabsorbed fatty acids, oxalate combines with sodium to form sodium oxalate, which is soluble and is absorbed in the colon (enteric hyperoxaluria). The development of calcium oxalate stones in Crohn disease requires an intact colon to absorb oxalate. Patients with ileostomies generally do not develop calcium oxalate stones, but they may develop uric acid or mixed stones.

Etiology

Three characteristics define the etiology of inflammatory bowel disease (IBD): (1) genetic predisposition; (2) an altered, dysregulated immune response; and (3) an altered response to gut microorganisms. However, the triggering event for the activation of the immune response in IBD has yet to be identified. Possible factors related to this event include a pathogenic organism (as yet unidentified) or an inappropriate response (ie, failure to downgrade the inflammatory response to an antigen, such as an alteration in barrier function). No mechanism has been implicated as the primary cause, but many are postulated. The lymphocyte population in persons with IBD is polyclonal, making the search for a single precipitating cause difficult. In any case, an inappropriate activation of the immune system leads to continued inflammation of the intestinal tract, both acute (neutrophilic) and chronic (lymphocytic, histiocytic). Several environmental risk factors have been proposed to contribute to IBD pathogenesis, but the results are inconsistent, and the limitations of the studies preclude drawing firm conclusions. The most consistent association described has been smoking, which increases the risk of Crohn disease. However, current smoking protects against ulcerative colitis, whereas former smoking increases the risk of ulcerative colitis. Dietary factors have also been inconsistently described. In some studies, high fiber intake and high intake of fruits and vegetables appear protective against IBD. The E3N prospective study found that high animal protein intake (meat or fish) carried a higher risk of IBD.

Genetics: Persons with IBD have a genetic susceptibility for the disease, and considerable research over the past decade has improved our understanding of the role of these genes. Note that these genes appear to be permissive (ie, allow IBD to occur), but they are not causative (ie, just because the gene is present does not necessarily mean the disease will develop). First-degree relatives have a 5- to 20-fold increased risk of developing IBD, as compared with persons from unaffected families. The child of a parent with IBD has a 5% risk of developing IBD. Twin studies show a concordance of approximately 70% in identical twins, versus 5-10% in nonidentical twins. Of patients with IBD, 10-25% are estimated to have a first-degree relative with the disease. Monozygous twin studies show a high concordance for Crohn disease but less so for ulcerative colitis. *Crohn disease:* An early discovery on chromosome 16 (*IBD1* gene) led to the identification of 3 single nucleotide polymorphisms (2 missense, 1 frameshift) in the *NOD2* gene (now called *CARD15*) as the first gene (*CARD15*) clearly associated with IBD (as a susceptibility gene for Crohn disease). *CARD15* is a polymorphic gene involved in the innate immune system. The gene has more than 60 variations, of which 3 play a role in 27% of patients with Crohn disease, primarily in patients with ileal disease. *Ulcerative colitis:* The genetic predisposition for ulcerative colitis appears to be lesser in magnitude than Crohn disease but consists of a set of genetic susceptibilities that shows significant overlap with Crohn disease. One genome-wide association study found a previously unknown susceptibility locus at ECM1 and also showed several risk loci that were common to both ulcerative colitis and Crohn disease. Genes that confer risk for both diseases appear to influence the immune milieu of the intestine, whereas the genes that influence only Crohn disease appear to be involved mainly in autophagy.

Smoking: The risk of developing ulcerative colitis is higher in nonsmokers and former smokers than in current smokers. The onset of ulcerative colitis occasionally appears to coincide with smoking cessation; however, this does not imply that smoking would improve the symptoms of ulcerative colitis. There has been limited success with the use of nicotine patches. Crohn disease patients have a higher incidence of smoking than the general population, and smoking appears to lessen the response to medical therapy.

Epidemiology

Racial, sexual, and age-related differences: The incidence and prevalence of inflammatory bowel disease (IBD) among Americans of African descent is estimated to be the same as the prevalence among

Americans of European descent, with the highest rates in the Jewish populations of middle European extraction. There is a higher prevalence along a north-south axis in the United States and in Europe, although trends show that the gap is narrowing. The male-to-female ratio is approximately 1:1 for ulcerative colitis and Crohn disease, with females having a slightly greater incidence. Both diseases are most commonly diagnosed in young adults (ie, late adolescence to the third decade of life). The age distribution of newly diagnosed IBD cases is bell-shaped; the peak incidence occurs in people in the early part of the second decade of life, with the vast majority of new diagnoses made in people aged 15-40 years. A second, smaller peak in incidence occurs in patients aged 55-65 years and is increasing. Approximately 10% of IBD patients are younger than 18 years.

International statistics: The highest rates of IBD are assumed to be in developed countries, and the lowest are considered to be in developing regions; colder-climate regions and urban areas have a greater rate of IBD than those of warmer climates and rural areas. Internationally, the incidence of IBD is approximately 0.5-24.5 cases per 100,000 person-years for ulcerative colitis and 0.1-16 cases per 100,000 person-years for Crohn disease. Overall, the prevalence for IBD is 396 cases per 100,000 persons annually. A review of IBD reported that the prevalence for Crohn disease in North America was 319 per 100,000 persons and 6.3 per 100,000 person-years in Asia and the Middle East. Time-trend analyses showed statistically significant increases in the incidence of IBD over time.

Prognosis

The standardized mortality ratio for inflammatory bowel disease (IBD) ranges from approximately 1.4 times the general population to 5 times the general population. Most of this increase appears to be in the Crohn disease population; the ulcerative colitis population appears to have the same mortality rate as the general population. The majority of studies indicate a small but significant increase in mortality associated with IBD. A frequent cause of death in persons with IBD is the primary disease ; infections and COPD/respiratory illness are other major causes of death. IBD is not a risk factor for cardiovascular mortality. Patients with IBD are more prone to the development of malignancy. Persons with Crohn disease have a higher rate of small bowel malignancy. Patients with pancolitis, particularly ulcerative colitis, are at a higher risk of developing colonic malignancy after 8-10 years of disease. The current standard of practice is to screen patients with colonoscopy at 1-2 year intervals once they have had the disease for greater than 10 years. In addition to long-term, disease-related complications, patients can also experience morbidity from prolonged medical therapy, particularly as a consequence of steroid exposure.

Ulcerative colitis: The average patient with ulcerative colitis has a 50% probability of having another flare during the next 2 years; however, patients may have only one flare over 25 years, and others may have almost persistent active disease. A small percentage of patients with ulcerative colitis have a single attack and no recurrence. Typically, remissions and exacerbations are characteristic of this disease, with acute attacks lasting weeks to months. Patients with ulcerative colitis limited to the rectum and sigmoid have a 50% chance of progressing to more extensive disease over 10 years and a 7.5% rate of colectomy over 5 years. Approximately 10% of patients presenting with proctitis will develop a pancolitis. Surgical resection for ulcerative colitis is considered "curative" for this disease, although patients may experience symptoms related to the ileal pouch (J-pouch), including acute and chronic pouchitis. Pouchitis is far more common in patients who have had a colectomy for ulcerative colitis than in those who have had a colectomy for familial adenomatous polyposis. Beyond 8-10 years after diagnosis, the risk of colorectal cancer increases by 0.5-1.0% per year. Surveillance colonoscopies with random biopsies reduce mortality from colorectal cancer in patients with ulcerative colitis by allowing the detection of low- or high-grade dysplasia and early stage carcinoma.

Crohn disease: The clinical course of Crohn disease is much more variable than that of ulcerative colitis, and it is dependent on the anatomic location and extent of the disease. Periodic remissions and exacerbations are the rule in Crohn disease. The relapse rate over 10 years is 90%, and the cumulative probability of requiring surgery over 10 years is approximately 38%. Terminal ileum location, fistulizing, and structuring disease are all independent risk factors for subsequent surgery. A review of the literature indicates that approximately 80% of patients who are in remission for 1 year will remain in remission over subsequent years. Patients with active disease in the past year have a 70% chance of having clinical disease activity in the following year. Approximately 20% of patients will have annual relapses, and 13% will have a course free of relapses. Less than 5% of patients with Crohn disease will have continually active disease. Surgery for Crohn disease is generally performed for complications (eg, stricture, stenosis, obstruction, fistula, bleeding, or abscess). Surgical intervention is an important treatment option for Crohn disease, but patients should be aware that it is not curative and that disease recurrence after surgery is high, mimicking the original disease pattern at the site of surgical anastomosis. Recurrence of perianal fistulas after medical or surgical treatment is common (59-82%). In one study, one year after surgery for Crohn disease, 20-37% of patients had symptoms suggestive of clinical recurrence, and endoscopic evidence of recurrent inflammation was in the neoterminal ileum in 48-93% of patients. Overall, the patient's quality of life with Crohn disease is generally lower than that of individuals with ulcerative colitis. Data suggest that in persons with Crohn colitis involving the entire colon, the risk of developing malignancy is equal to that in persons with ulcerative colitis; however, the risk is much smaller (albeit poorly quantified) in most patients with Crohn disease primarily involving the small bowel. Intestinal cancer may become a more important long-term complication in patients with Crohn disease because of longer survival. Studies support evidence that specific *CARD15* mutations are associated with the intestinal location of the disease, as well as course and prognosis, and are correlated with the propensity for developing ileal strictures & with an early onset of disease.

Complications of IBD disease:

Intestinal complications: IBD can be associated with several gastrointestinal complications, including risk of hemorrhage, perforation, strictures, and fistulas—as well as perianal disease and related complications, such as perianal or pelvic abscesses, toxic megacolon (complicating acute severe colitis), and malignancy (colorectal cancer, cholangiocarcinoma complicating primary sclerosing cholangitis).

Extraintestinal complications: Extraintestinal complications occur in approximately 20-25% of patients with IBD. In some cases, they may be more symptomatic than the bowel disease itself. These include osteoporosis (usually a consequence of prolonged corticosteroid use), hypercoagulability resulting in venous thromboembolism, anemia, gallstones, primary sclerosing cholangitis, aphthous ulcers, iritis (uveitis) and episcleritis, and skin complications (pyoderma gangrenosum, erythema nodosum).

Table 1, on next page, summarizes the rates of the most common extraintestinal complications in patients with IBD.

Table 1.

Complication	Prevalence
Scleritis	18%
Anterior uveitis	17%
Gall stones (particularly in Crohn disease)	13-34%
Inflammatory arthritis	10-35%
Anemia	9-74%
Aphthous stomatitis	4-20%
Osteoporosis	2-20%
Erythema nodosum	2-20%

The Swiss National IBD Cohort Study also demonstrated the risks of extraintestinal complications of IBD; their results are summarized in Table 2, below.

Complication	Crohn Disease	Ulcerative Colitis
Arthritis	33%	4%
Aphthous stomatitis	10%	4%
Uveitis	6%	3%
Erythema nodosum	6%	3%
Ankylosing spondylitis	6%	2%
Psoriasis	2%	1%
Pyoderma gangrenosum	2%	2%
Primary sclerosing cholangitis	1%	4%

Patient Education

Because inflammatory bowel disease (IBD) is a chronic, often lifelong disease that is frequently diagnosed in young adulthood, increasing patient knowledge improves medical compliance and assists in the management of symptoms. Encourage the patient to join an IBD support group.

History

The manifestations of inflammatory bowel disease (IBD) generally depend on the area of the intestinal tract involved. The commonly experienced symptoms of Crohn disease include recurrent abdominal pain and diarrhea. Sometimes, the diagnosis may be delayed by several months to a few years, as these symptoms are not specific for IBD. Patients with IBD have irritable bowel syndrome (IBS), cramping, irregular bowel habits, and passage of mucus without blood or pus. Systemic symptoms are common in IBD and include weight loss, fever, sweats, malaise, and arthralgias. A low-grade fever may be the first warning sign of a flare. Patients are commonly fatigued, which is often related to the pain, inflammation, and anemia that accompany disease activity. Recurrences may occur with emotional stress, infections or other acute illnesses, pregnancy, dietary problems, use of cathartics or antibiotics, or nonadherence to therapy. Children may present with growth retardation and delayed or failed sexual maturation. In 10-20% of cases, patients present with extraintestinal manifestations, including arthritis, uveitis, or liver disease (see Complications). Grossly bloody stools, occasionally with tenesmus, although typical of ulcerative colitis, are less common in Crohn disease. Stools may be formed, but loose stools predominate if the colon or the terminal ileum is involved extensively. Fifty percent of patients with Crohn disease may present with perianal disease (eg, fistulas, abscesses). Occasionally, acute right lower quadrant pain and fever, mimicking appendicitis or intestinal obstruction, may be noted. Weight loss is observed more commonly in Crohn disease than in ulcerative colitis because of the malabsorption associated with small bowel disease, or small bowel disease may act as an appetite deterrent. In addition, patients may reduce their food intake in an effort to control their symptoms. The World Gastroenterology Organization (WGO) indicates the following symptoms may be associated with inflammatory damage in the digestive tract : Diarrhea: mucus or blood may be present in the stool; can occur at night; incontinence may occur. Constipation: this may be the primary symptom in ulcerative colitis and limited to the rectum; obstipation may occur and may proceed to bowel obstruction. Bowel movement abnormalities: pain or rectal bleeding may be present, as well as severe urgency and tenesmus. Abdominal cramping and pain: commonly present in the right lower quadrant in Crohn disease; occur periumbilically or in the left lower quadrant in moderate to severe ulcerative colitis. Nausea and vomiting: occurs more often in Crohn disease than in ulcerative colitis). Other considerations in include a family history of IBD, celiac disease, or colorectal cancer; the use of medications such as antibiotics and nonsteroidal anti-inflammatory drugs (NSAIDs); the presence of mood disorders; the use of tobacco; and recent travel.

Physical Examination

Fever, tachycardia, dehydration, and toxicity may occur in patients with inflammatory bowel disease (IBD). Pallor may also be noted, reflecting anemia. The prevalence of these factors is directly related to the severity of the attack. Toxic megacolon is a medical emergency. Patients appear septic; have high fever, lethargy, chills, and tachycardia; and have increasing abdominal pain, tenderness, and distention. Patients with Crohn disease may develop a mass in the right lower quadrant. Perianal complications (eg, perianal fissures or fistulas, abscesses, rectal prolapse) may be observed in up to 90% of patients with this disease. Common presenting signs include occult blood loss and low-grade fever, weight loss, and anemia. The rectal examination often reveals bloody stool or positive Hemoccult examination. Growth retardation may be the only presenting sign of IBD in young patients. The physical examination should also include a search for extraintestinal manifestations, such as iritis, episcleritis, arthritis, and dermatologic involvement. (see Complications.)

Diagnostic Considerations

Approximately 90% of patients with Crohn disease have involvement of the terminal ileum and/or right colon. Pediatric patients are more likely (about 20%) to present with disease limited to the small intestine, although very young children often present with purely colonic disease. Occasionally, gastric or duodenal Crohn disease manifests as seemingly refractory peptic ulcer disease. Consider anorexia and bulimia in patients with suspected inflammatory bowel disease (IBD) and irritable bowel syndrome (IBS), because not only are abdominal pain, weight loss, and vomiting consistent in these 4 conditions, but IBD is frequently diagnosed in late-teen and young-adult patients, which are also the peak years for anorexia and bulimia. Due to the nonspecific gastrointestinal symptoms of Crohn disease and ulcerative colitis, several other diagnoses (see below) must be considered before establishing a diagnosis of Crohn disease or ulcerative colitis, particularly in the absence of typical endoscopic findings and in populations at higher risk for other diagnoses. Note that historically—and especially when a preoperative computed tomography (CT) scanning has not been done—Crohn disease is frequently diagnosed at the time of laparotomy for presumed appendicitis. Another disease in the differential diagnosis is salmonellosis, which can present as bloody diarrhea.

Diarrhea: Consider the following conditions in patients with diarrhea as a dominant symptom: Celiac disease, Microscopic colitis, Irritable bowel syndrome, Lactose intolerance, Functional diarrhea, Gastrointestinal infections (eg, intestinal tuberculosis, amebiasis, chronic *Yersinia* infection, and antibiotic-associated colitis/*Clostridium difficile* infection), Behcet disease, AIDS, C1 esterase deficiency, hereditary angioedema, Colorectal malignancy (eg, adenocarcinoma, lymphoma).

Abdominal pain, gastrointestinal bleeding, and/or intestinal ulceration: In patients with predominant abdominal pain, gastrointestinal bleeding, and/or intestinal ulceration, consider the following conditions in the differential diagnosis: Ischemic colitis, Radiation-induced colitis, Arteriovenous malformations, Nonsteroidal anti-inflammatory drug (NSAID) enteropathy, Behcet disease, Intestinal tuberculosis, Colorectal malignancy.

Differential Diagnoses

Anorexia Nervosa, Appendicitis, Bulimia, Celiac Sprue, Clostridium Difficile Colitis, Collagenous and Lymphocytic Colitis, Cytomegalovirus, Cytomegalovirus Colitis, Diverticulitis, Eosinophilic Gastroenteritis, Food Poisoning, Gastroenteritis, Bacterial, Gastroenteritis, Viral, Giardiasis, Intestinal Motility Disorders, Intestinal Radiation Injury, Irritable Bowel Syndrome, Lactose Intolerance, Salmonellosis.

Approach Considerations

Several laboratory studies are of value in assisting with the management of inflammatory bowel disease (IBD) and provide supporting information. However, no laboratory test is specific enough to adequately and definitively establish the diagnosis of IBD. Laboratory values may be used as surrogate markers for inflammation and nutritional status and to look for deficiencies of necessary vitamins and minerals. Serologic studies have been proposed to help diagnose IBD and to differentiate Crohn disease from ulcerative colitis, but such studies are not recommended for routine diagnosis of Crohn disease or ulcerative colitis. In individuals who are immunosuppressed, are from third world countries, or have a history of travel, intestinal tuberculosis (TB) may need to be excluded. In such cases, tuberculin purified protein derivative (PPD) or interferon-gamma assays (eg, QuantiFERON-TB, T-SPOT, TB test) may be indicated, as well as culture for amebiasis, giardiasis, *Strongyloides* infection, and studies for histoplasmosis and coccidioidomycosis. Chest radiography may exclude pulmonary TB, but this imaging modality does not exclude extrapulmonary TB.

Laboratory Studies

Hematologic tests

Complete blood cell count: The components of the complete blood cell (CBC) count can be useful indicators of disease activity and iron or vitamin deficiency. An elevated white blood cell (WBC) count is common in patients with active inflammatory disease and does not necessarily indicate infection. Anemia is common and may be either an anemia of chronic disease (usually normal mean corpuscular volume [MCV]) or an iron deficiency anemia (MCV is often low). Anemia may result from acute or chronic blood loss malabsorption (iron, folate, and vitamin B12) or may reflect the chronic disease state. Note that the MCV can be elevated in patients taking azathioprine (Imuran) or 6-mercaptopurine (6-MP). Generally, the platelet count is normal, or it may be elevated in the setting of active inflammation.

Nutritional evaluation: Vitamin B12 evaluation, iron studies, RBC folate, nutritional markers: Vitamin B12 deficiency can occur in patients with Crohn disease who have significant terminal ileum disease or in patients who have had terminal ileum resection. The standard replacement dose of vitamin B12 is 1000 mg subcutaneously (SC) every month, because oral replacement is often insufficient. Serum iron studies should be obtained at the time of diagnosis, because active IBD is a source for GI blood loss, making iron deficiency common. A microcytic hypochromic anemia suggests iron deficiency; if confirmed with serum iron/total iron-binding capacity (TIBC), iron can be replaced either enterally or parenterally. For parenteral replacement, intravenous (IV) iron sucrose can be used, and dosing is based on the table in the package insert, with a maximum of 30 mL (1500 mg) at once. Although folate deficiency is not common in persons with IBD, several concerns have been raised regarding this vitamin. Sulfasalazine (Azulfidine) is a folate reductase inhibitor and may inhibit normal uptake of folate; thus, many practitioners commonly administer folate supplements in patients taking sulfasalazine. Folate supplements are indicated in all women who are pregnant to help prevent neural tube defects; this is particularly true for patients with IBD, and supplementation with 2 mg/day or more (rather than the usual 1 mg/day) should be considered in those on sulfasalazine. Nutritional status can be assessed by serum albumin, prealbumin, and transferrin levels. However, note that transferrin is an acute-phase reactant that can be falsely elevated in persons with active IBD. Hypoalbuminemia may reflect malnutrition because of poor oral intake or because of the protein-losing enteropathy that can coexist with active IBD.

ESR and CRP levels: The erythrocyte sedimentation rate (ESR) and C-reactive protein (CRP) level are often used as serologic markers for inflammation, but they are not specific for IBD. However, measuring such inflammatory markers also aids in monitoring disease activity and response to treatment. A small but significant number of patients with Crohn disease or ulcerative colitis may not have elevated ESR or CRP levels even in the setting of significant active inflammation. In addition, inflammatory markers may be elevated in the setting of superimposed intestinal or extraintestinal infections. Fecal calprotectin has been proposed as a noninvasive surrogate marker of intestinal inflammation in IBD. As colorectal neoplasia and gastrointestinal infection also increase fecal calprotectin, this marker is not in widespread use. Note that relatives of patients with IBD may also have elevated levels of fecal calprotectin (with unknown degrees of inflammation).

Serologic Studies

pANCA and ASCA tests

Perinuclear antineutrophil cytoplasmic antibodies (pANCA) have been identified in some patients with ulcerative colitis, and anti-*Saccharomyces cerevisiae* antibodies (ASCA) have been found in patients with Crohn disease. The combination of positive pANCA and negative ASCA has high specificity for ulcerative colitis, whereas the inverse pattern—positive ASCA, negative pANCA—is more specific for Crohn disease. However, false-positive (and false-negative) results are not uncommon; therefore, at this time, serologic markers cannot be used to definitively rule in or exclude inflammatory bowel disease (IBD). Note that a variant of Crohn disease particularly involving the colon may result in a positive pANCA test, which may complicate the diagnosis. Serum response to anti-CBir1, an antibody associated with the presence of IBD, has been shown to differentiate pANCA-positive results in ulcerative colitis versus ulcerative colitis–like Crohn disease. Patients with Crohn disease who have a greater number of positive ASCA may be at a greater risk for complications such as strictures and fistulas, and they may also be at a higher risk for surgery. However, serologic markers do not appear to predict response to medical therapy, and there is currently insufficient evidence to recommend the use of antibody testing to predict responses to treatment or surgery in patients with IBD.

Stool Studies

Before making a definitive diagnosis of idiopathic inflammatory bowel disease (IBD), perform a stool culture, ova and parasite studies, bacterial pathogens culture, and evaluation for *Clostridium difficile* infection.[1] At a minimum, a *C difficile* toxin assay should be performed on any patient hospitalized with a flare of colitis, because pseudomembranous colitis is commonly superimposed on IBD colitis. Note that the level of the inflammatory marker calprotectin in feces correlates significantly with colonic inflammation in both ulcerative colitis and Crohn disease. Assessment for *Cytomegalovirus* colitis should be performed in cases refractory to steroids. Amebiasis can be difficult to

identify from the stool; therefore, consider serologic testing. As many as 50-80% of cases of acute terminal ileitis may be due to *Yersinia* enterocolitis infections. This produces a picture of pseudoappendicitis. As with IBD, yersiniosis has a high frequency of secondary manifestations, such as erythema nodosum and monoarticular arthritis. Thus, in the right clinical setting, a suspicion for *Yersinia* should be considered.

Radiography

Upright chest and abdominal radiography

Abdominal radiography may allow for assessment of the kidneys, ureters, and bladder for nephrolithiasis and the vertebral bodies for osteopenia or osteoporosis and sacroileitis. If severe fulminant colitis is present, abdominal radiography may reveal an edematous, irregular colon with thumbprinting. Occasionally, pneumatosis coli (air in the colonic wall) may be present. Free air and evidence of toxic megacolon, which appears as a long continuous segment of air-filled colon greater than 6 cm in diameter, indicates a surgical emergency.

Ultrasonography

Ultrasonography (US) is a non-invasive technique in diagnosing Crohn disease. Although this technique has a sensitivity of 84% and a specificity of 92%, it has less accuracy when disease is located proximal to the terminal ilium. Ultrasonography, magnetic resonance imaging (MRI), and computed tomography (CT) scanning have similar accuracy for the entire bowel and are reliable in identifying fistulas, abscesses, and stenosis; however, US may lead to false positives for abscesses. US and MRI are often preferred over CT scanning because of the lack of radiation, especially in younger patients.

Colonoscopy and Flexible Sigmoidoscopy

Colonoscopy

Colonoscopy is one of the most valuable tools available to the physician for the diagnosis and treatment of inflammatory bowel disease (IBD), although its limitations must be recognized. Foremost, not all mucosal inflammation is idiopathic IBD. Infectious causes of inflammation must always be considered, as should diverticulitis and ischemia (which are far more common as new diagnoses in an elderly population than IBD, despite the similar colonoscopic and histologic appearance). When used appropriately, colonoscopy can help determine the extent and severity of colitis, assist in guiding treatment, and provide tissue to assist in the diagnosis. In skilled hands, the colonoscope can frequently reach the terminal ileum and permit assessment of inflammation to assist in the diagnosis or exclusion of Crohn disease. Inflammation may occasionally occur in the terminal ileum in patients with ulcerative colitis; this is referred to as a backwash ileitis and is mild, is nonulcerating, and may occur when a widely patent ileocecal valve is present. (See the following images.)

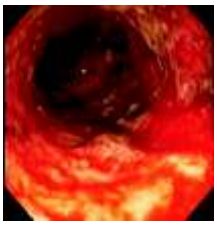

Severe colitis noted during colonoscopy in a patient with inflammatory bowel disease. The mucosa is grossly denuded, with active bleeding noted. The patient had her colon resected very shortly after this view was obtained.

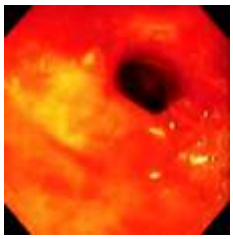

Stricture in the terminal ileum noted during colonoscopy in a patient with inflammatory bowel disease. This image depicts a narrowed segment visible upon intubation of the terminal ileum with the colonoscope. Relatively little active inflammation is present, indicating that this is a cicatrix stricture.

Colonoscopy or sigmoidoscopy reveals that the rectum is almost always involved in ulcerative colitis, but it is frequently spared in Crohn disease. The disease can be limited to the rectum (proctitis); to the rectum, sigmoid, and descending colon (left-sided colitis); or to the entire colon (pancolitis). Ulcerative colitis does not involve any other segment of the GI tract. Colectomy is curative. Colonoscopy with ileoscopy in the assessment of Crohn disease has a sensitivity of 74% and a specificity of 100%, leading to a positive predictive value of 100% as a diagnostic test. When paired with small bowel follow-through, the sensitivity of this pair of diagnostic tests is increased to 78%, with a continued positive predictive value of 100%. Colonoscopy can also be used for therapeutic intervention in patients with IBD. The most common therapeutic use is stricture dilation in persons with Crohn disease. Colonic, anastomotic, and even small bowel strictures can often be dilated using pneumatic through-the-scope dilators. Intralesional injection of steroids (eg, triamcinolone at 5 mg in 4 quadrants) may help, but it is usually of transient value and has yet to be demonstrated in controlled trials. Patients with IBD who are undergoing endoscopic procedures may have higher complication rates than the general population. The risks of colonoscopy apply (eg, reaction to medication, bleeding, perforation), and the risk of bleeding is increased in the presence of inflammation. The risk of perforation is also increased, particularly in patients taking high doses of steroids long term or who have severe colitis. Colonoscopy also plays an important role in surveillance for colorectal cancer in patients with IBD. The utility of endoscopic surveillance can further be optimized by autofluorescence plus high-resolution endoscopy, chromoendoscopy-guided confocal laser microscopy, and confocal laser microscopy in combination with narrow-band imaging and high-resolution endoscopy, as well as chromoendoscopy with methylene-blue dye, spray-targeted biopsies.

Flexible sigmoidoscopy

Flexible sigmoidoscopy is useful for a preliminary diagnosis in patients with chronic diarrhea or rectal bleeding; however, because of the limited length of the scope (60 cm), it can only help diagnose distal ulcerative colitis or proctitis. Rarely, Crohn colitis can be diagnosed based on flexible sigmoidoscopy findings. Note that sigmoid inflammation, particularly in older patients, may be confused with diverticulitis or ischemia.

Histologic Findings

Ulcerative colitis

Ulcerative colitis is a superficial inflammation of the bowel wall almost entirely limited to the large bowel (when the cecum is involved, there may be some inflammation in the distal-most ileum, the so-called "backwash ileitis"). Only in complicated cases such as evolution into toxic megacolon are the deeper layers of the bowel wall involved with the inflammatory process. Ulcerative colitis primarily involves the mucosa and the submucosa, with formation of crypt abscesses and mucosal ulceration. The mucosa typically appears granular and friable. In more severe cases, pseudopolyps form, consisting of areas of hyperplastic growth with swollen mucosa surrounded by inflamed mucosa with shallow ulcers. In severe ulcerative colitis, inflammation and necrosis can extend below the lamina propria to involve the submucosa and the circular and longitudinal muscles. Inflammation in ulcerative colitis almost always involves the rectum and is contiguous, regardless of the extent of the colon involved. The exception to this rule is that the initial inflammation may appear patchy during colonoscopy that is performed very early in the ulcerative colitis process, although biopsy specimens of intervening normal-appearing mucosa often do reveal inflammation. The intestinal inflammation of ulcerative colitis only involves the colon.

Biopsy specimens demonstrate neutrophilic infiltrate along with crypt abscesses and crypt distortion. Granulomas do not occur in ulcerative colitis. (See the following images.)

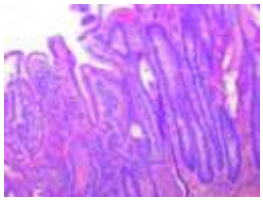

Chronic architectural changes in ulcerative colitis. Note the crypt branching and irregularity of size and shape, with an increase in chronic inflammatory cells in the lamina propria.

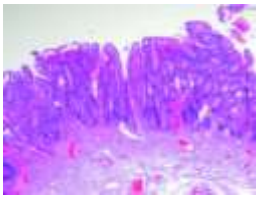

Low-power image from a colon biopsy in a patient with ulcerative colitis illustrates changes limited to the mucosa. These changes include chronic alteration of the crypt architecture and an increase in chronic inflammatory cells in the lamina propria.

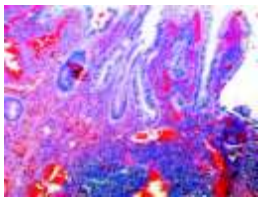

Chronic architectural changes in ulcerative colitis. Note the trifid crypt.

The typical histologic findings of ulcerative colitis include expansion of chronic inflammation in the mucosa and, in active cases, the presence of acute inflammation. In mildly active cases, there is an acute cryptitis that progresses to crypt abscesses in moderately active cases. In severe cases, mucosal ulcers develop as a result of the ongoing acute inflammatory process. Areas of relatively preserved mucosa between ulcerated areas may have a polypoid appearance grossly and are referred to as "pseudopolyps." In cases of many years' duration, dysplasia of the large bowel mucosa may develop and signifies an increased risk for the development of colorectal adenocarcinoma. (See the images below.)

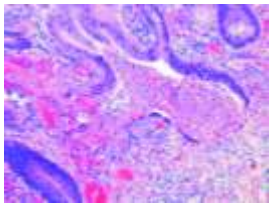

High-power view of a crypt abscess in ulcerative colitis shows the crypt to be dilated and filled with neutrophils and debris.

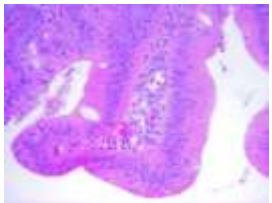

This is an example of low-grade glandular dysplasia in a patient with longstanding ulcerative colitis. Note the loss of mucin, nuclear hyperchromasia, and nuclear pseudostratification. See the next image.

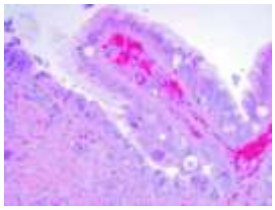

High-grade dysplasia in the same patient as the previous image. There is significant cytologic atypia, with rounding of the nuclei and a greater degree of pseudostratification.

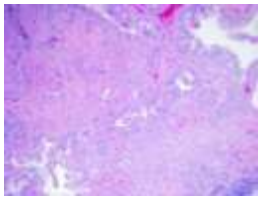

Histologic section from another location in the same patient as the previous image. This field shows glands that are suspicious for invasive carcinoma.

Crohn disease

The entire intestinal wall is involved with inflammation in Crohn disease. Biopsy specimens may demonstrate granulomas (approximately 50% of the time). The presence of granulomas is often helpful for making the diagnosis but is not necessary. Because biopsy specimens obtained at colonoscopy are generally superficial mucosal tissue samples, the pathologist may have difficulty making a definitive diagnosis of ulcerative colitis or Crohn disease based on histologic findings alone. However, histology also helps rule out other causes of inflammation, including infectious colitis and ischemic colitis. The characteristic pattern of inflammation in Crohn disease is a transmural involvement of the bowel wall by lymphoid infiltrates that contains sarcoidlike granulomas in about half of the cases (most commonly in the submucosa). Also characteristic are proliferative changes in the muscularis mucosa and in the nerves scattered in the bowel wall and myenteric plexus. In the involved foci of the small and large bowel, Paneth cell hyperplasia is frequent and areas of pyloric metaplasia may be seen. In full-blown cases, long and deep fissurelike ulcers form. (See the following images.)



Histologic features of chronic Crohn colitis with crypt atrophy and branching, as well as lymphocytic infiltrate. Hematoxylin-eosin staining. Courtesy of Dr E. Ruchelli.

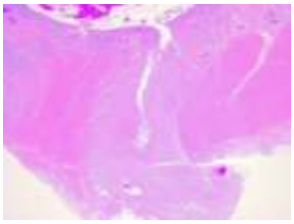

Deep knifelike, fissuring, transmural ulcer in Crohn disease.

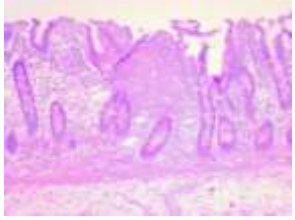

Granuloma in the mucosa of a Crohn disease patient.

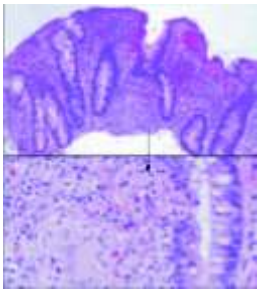

Colonic granuloma in a patient with Crohn disease.

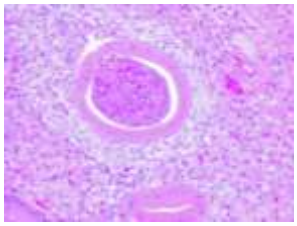

Hematoxylin-eosin staining. A crypt abscess demonstrating active, neutrophilic inflammation in Crohn disease

Approach Considerations

The care of a patient with inflammatory bowel disease (IBD) can be either medical or surgical in nature or, in many patients, a combination of both. The management algorithm is also dependent on whether the diagnosis is Crohn disease or ulcerative colitis. The medical approach for patients with IBD is both symptomatic care (ie, relief of symptoms) and mucosal healing following a stepwise approach to medication, with escalation of the medical regimen until a response is achieved. The 2 goals of therapy are the achievement of remission (induction) and the prevention of disease flares (maintenance). Note that a top-down approach, with earlier introduction of biologics and immunomodulators, is frequently advocated to forestall complications. The concept of deep mucosal healing, particularly in Crohn disease, is becoming increasingly advocated. There are several studies, primarily involving anti-TNF agents (and occasionally immune modifiers); that have shown that the elimination of inflammation (as demonstrated by endoscopic and histologic criteria) results in a decrease in the rate of surgery, the use of corticosteroids, and the rate of hospitalization. This supports the use of immune-modifying agents (mercaptopurine or azathioprine) or one of the anti-TNF agents earlier in the course of IBD.

INTERPRETATION

Average healthy adults defecate from three times a day to three times a week. Common pattern is once a day. The stool tends to be soft and bulky on a diet high in vegetables and small and dry on a diet high in meat. Two thirds of the stool weight is attributable to its water content. The normal brown colour is of still undetermined origin. The odour results from indole and skatole, produced by bacteria from tryptophan.

Faeces are Composed of:

Waste residue of indigestible material in food, Bile (pigments and salts), Intestinal secretions, including mucus, Leucocytes that migrate from the bloodstream, Shed epithelial cells, Large numbers of bacteria that make up to one-third of total solids, Inorganic material (10-20%) that is chiefly calcium and phosphates, Digested food (present in very small quantities).

Specimen Collection:

A wide mouthed jar with a screw cap is good enough, provided it is neat, clean, and without any extraneous material in it. It should, however, never be overfilled and should be opened slowly to release the gas that accumulates frequently in it (if not done so, the contents may be released explosively). Since rectal evacuation is not completely at will and faeces passed correlate very poorly with the food consumed; hence, collection should be done over a period of 3 days. The accuracy of this method can be enhanced somewhat by having the patient ingest carmine dye (0.3 gm) and charcoal (1 gm) at the beginning and the end of a collecting period, respectively, collecting the stools from the beginning of the appearance of the dye to the beginning of the appearance of the charcoal.

Be Careful:

Faeces should be urine free when collected. Collect the entire stool and transfer to another container by a tongue blade. Deliver to the laboratory immediately after collection. Warm stools are best for detecting ova and parasites. Do not refrigerate for ova and parasites. Some coliform bacilli produce antibiotic substances that destroy enteric pathogens. Refrigerate stool if it cannot be examined immediately. Never place a stool in an incubator. A diarrhoeal stool will usually give good results. A freshly passed stool is the specimen of choice. Preferably, stool specimens should be collected before antibiotic therapy is initiated and as early in the course of disease as possible. Only a small amount of stool is needed; the size of a walnut. If mucus and blood are present, they should be included in part of the specimen to be examined. Do not use a stool that has been passed into the toilet bowl or that has been contaminated with barium or other X-ray medium. Label all stool specimens with patient's name, date, and reason for examination/testing.

Interfering Factors: Meat interferes with some tests and should usually be omitted from the diet for 3 days before a test for blood (not necessary for the guaiac method). Stool specimens from patients receiving barium, bismuth, oil, or antibiotics are not satisfactory. Bismuth from paper towels and toilet tissues interferes with tests.

Normal Values in Stool Analysis

Macroscopic examination	Normal
Colour	Brown
Odour	Varies with pH stool and depends upon bacterial fermentation and putrefaction
Consistency	Plastic: not unusual to see seeds and vegetable skins: soft and bulky in a high vegetable diet: small and dry in a high meat diet
Size and shape	Formed
Gross blood	Absent
Mucus	Absent
Pus	Absent
Parasites	Absent
Fat	Colourless, neutral fat (18%) and fatty acid crystals and soaps
Undigested	None to small amount food, meat fibres, starch, trypsin
Eggs and segments of parasites	Absent
Yeasts	Absent
Leucocytes	Absent
Chemical examination	**Normal**
pH	Neutral to weakly alkaline
Adult	7.0-7.5
Newborn	5.0-7.0
Bottle-fed infants	Neutral to slightly alkaline pH of 7.0-8.0
Breast-fed infants	Slightly acidic
Occult blood	Negative
Urobilinogen	50-300 mg/24 hr
Porphyrins	Coproporphyrins<200µg/24 hr. Protoporphyrins<1500µg/24 hr Uroporphyrins< 100µg/24 hr
Nitrogen	1-2 gm/24 hr
Bile	Negative in adults, positive in children
Trypsin	Positive in small amounts in adults, in greater amounts in normal children.

Inspection of Faeces:

A simple inspection of faeces may lead to a diagnosis of parasitic infection, obstructive jaundice, diarrhoea, malabsorption, rectosigmoidal obstruction, dysentery or ulcerative colitis or gastrointestinal tract bleeding.

Inspection of faeces

Type of stool	Likely reason
Watery stool	Diarrhoea
Large amount of mushy, foul smelling, grey stool that floats on water	Steatorrhea
Little firm, spherical masses	Constipation (irritable colon syndrome, overuse of laxatives)
Narrow ribbon- like stool	Spastic bowel or rectal narrowing or stricture
Clay coloured	Obstructive jaundice or presence of Barium sulphate
Reddish stool	Blood from lower gastrointestinal tract, beets consumption or BSP use
Black tarry stool	Bleeding from upper GIT. Iron, bismuth or charcoal consumption
Green stool	Ingestion of spinach, etc. Calomel, presence of biliverdin seen in patients taking antibiotics orally
Parasites	Parasitic infestation

Note the quantity, form, consistency and colour of the stool (Table 7.2).

Interfering Factors: Stool darkens on standing. Colour is influenced by diet, food dyes, certain foods, and drugs. a. Yellow to yellow green colour occurs in the stool of breast-fed infants who lack normal intestinal flora. It also occurs in sterilisation of bowel by antibiotic, b. Green colour occurs in diets high in chlorophyll-rich vegetables and with use of the drug calomel, c. Black or very dark brown colour may be due to drugs such as iron, charcoal, and bismuth, to foods such as cherries, or to an unusually high proportion of meat in the diet, d. Light-coloured stool with little odour may be due to diets high in milk and low in meat, e. Clay like colour may be due to a diet with excessive fat intake or barium used in Xray examination, f. Red colour may be due to a

diet high in beet or use of drugs such as BSP, g. Drug-induced colour changes are given below: Black-iron salts, bismuth salts, charcoal, Green-mercurous chloride, indomethacin, calomel, Green to blue-dithiazanine, Brown staining-anthraquinones, Red- phenolphthalein, pyruvinium pamoate, tetracyclines in syrup, BSP, Yellow-santonin, Yellow to brown-senna, Light-sitosterols, Whitish discolouration-antacids, Orange red-phenazopyridine, Pink to red to black-anticoagulants (excessive dose) salicylates causing internal bleeding.

Pus: Patients with chronic ulcerative colitis and chronic bacillary dysentery frequently pass large quantities of pus with the stool that has to be examined microscopically. It may also occur in localised abscesses or fistulas communicating with sigmoid rectum or anus. Large amounts of pus NEVER accompany amoebic colitis. No inflammatory exudate is seen in the watery stools of patients with viral gastroenteritis.

Mucus: Even in slightest quantity is abnormal (see Table 7.3).

Mucous in stool- causes

Remarks	Causes
Translucent gelatinous mucus clinging to the surface of the formed stool	Spastic constipation or mucous colitis. In emotionally disturbed patients and may result from excessive straining.
Bloody mucus clinging to stool mass	Neoplasm, inflammation of rectal canal.
Mucus with pus and blood	Ulcerative olitis, bacillary dysentery, ulcerating carcinoma of the colon and more rarely, acute diverticulitis or intestinal tuberculosis.
Copious mucus, upto 3-4 litres of mucus per day	Villous adenoma of the colon (may lead to dehydration and hypokalaemia)

Odour and pH:

Normal Values:

Characteristic odour varies with the pH of stool; normal pH is neutral or weakly alkaline. The pH is dependent on bacterial fermentation and putrefaction in the bowel. Substances called indole and skatole, formed by intestinal putrefaction and fermentation, are mainly responsible for the odour of normal stools.

Interfering Substances:

Carbohydrate fermentation changes pH to acidic. Protein breakdown changes the pH to alkaline.

BOUQUET

In Lighter Vein

Before performing a baptism, the priest approached the young father and said solemnly, "Baptism is a serious step. Are you prepared for it?"

"I think so," the man replied. "My wife has made appetizers and we have a caterer coming to provide plenty of cookies and cakes for all of our guests."

"I don't mean that," the priest responded. "I mean, are you prepared spiritually?"

"Oh, sure," came the reply. "I've got a keg of beer and a case of whiskey.

BLONDE JOKE

January – Took new scarf back to store because it was too tight.

February – Fired from pharmacy job for failing to print labels.... Hellllloooo!!!..... Bottles won't fit in printer!!!

March – Got really excited.... finished jigsaw puzzle in 6 months..... Box said ' 2-4 years!'

April – Trapped on escalator for hours ... Power went out!!!

May – Tried to make Kool Aid.... wrong instructions.... 8 cups of water won't fit into those little packets!!!

June – Tried to go water skiing..... Couldn't find a lake with a slope.

July – Lost breast stroke swimming competition.... Learned later, the other swimmers cheated, they used their arms!!!

August – Got locked out of my car in rain storm.... Car swamped because soft-top was open.

September – The capital of California is C.... isn't it???

October – Hate M & M's..... They are so hard to peel.

November – Baked turkey for 4 ½ days.... Instructions said 1 hour per pound and I weigh 108!!

December – Couldn't call 911. 'Duh'.... there's no 'eleven' button on the stupid phone!!!

Wisdom Whispers

The Real Meaning of Peace

"There once was a king who offered a prize to the artist who would paint the best picture of peace. Many artists tried. The king looked at all the pictures. But there were only two he really liked, and he had to choose between them.

One picture was of a calm lake. The lake was a perfect mirror for peaceful towering mountains all around it. Overhead was a blue sky with fluffy white clouds. All who saw this picture thought that it was a perfect picture of peace.

The other picture had mountains, too. But these were rugged and bare. Above was an angry sky, from which rain fell and in which lightning played. Down the side of the mountain tumbled a foaming waterfall. This did not look peaceful at all. But when the king looked closely, he saw behind the waterfall a tiny bush growing in a crack in the rock. In the bush a mother bird had built her nest. There, in the midst of the rush of angry water, sat the mother bird on her nest - in perfect peace.

Which picture do you think won the prize? The king chose the second picture. Do you know why? "Because," explained the king, "peace does not mean to be in a place where there is no noise, trouble, or hard work. Peace means to be in the midst of all those things and still be calm in your heart. That is the real meaning of peace.

Brain Teasers

DIAGNOSE THE FOLLOWING INTESTINAL CONDITIONS FROM THE PICTURES GIVEN.

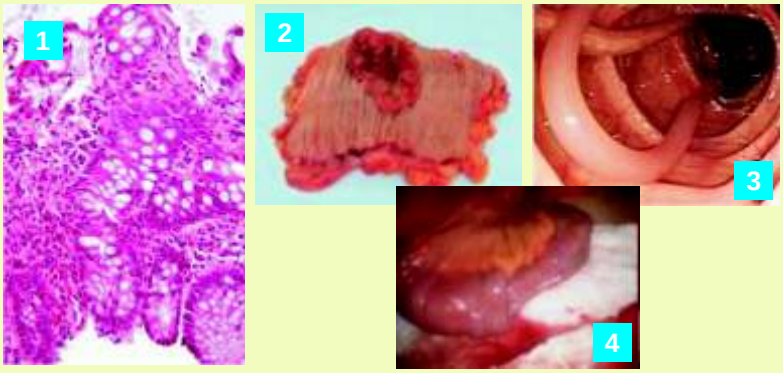

Answers: 1. Inflammatory Bowel Disease. 2.Colorectal carcinoma. 3.Roundworms in intestine. 4.Intussusception.

TROUBLESHOOTING

FOBT

Description: Fecal occult blood (FOB) refers to blood in the feces that is not visibly apparent. A fecal occult blood test (FOBT) checks for hidden (occult) blood in the stool (feces). Newer tests look for globin, DNA, or other blood factors including transferrin, while conventional stool guaiac tests look for heme.

Purpose: Fecal occult blood testing (FOBT), as its name implies, aims to detect subtle blood loss in the gastrointestinal tract, anywhere from the mouth to the colon. Positive tests ("positive stool") may result from either upper gastrointestinal bleeding or lower gastrointestinal bleeding and warrant further investigation for peptic ulcers or a malignancy (such as colorectal cancer or gastric cancer). The test does not directly detect colon cancer but is often used in clinical screening for that disease, but it can also be used to look for active occult blood loss in anemia or when there are gastrointestinal symptoms.

Nomenclature: In 2007 the nomenclature of overt, obscure and occult bleeding was clarified. The different methods of testing for "fecal occult blood" as broadly considered actually test for particular components of blood or for aberrantly expressed cellular markers from the intestinal mucosa.

Methodology: There are four methods in clinical use for testing for occult blood in feces. These look at different properties, such as antibodies, heme, globin, or porphyrins in blood, or at DNA from cellular material such as from lesions of the intestinal mucosa. Fecal Immunochemical Testing (FIT), and immunochemical fecal occult blood test (iFOBT). FIT products utilize specific antibodies to detect globin. FIT screening is more effective in terms of health outcomes and cost compared with guaiac FOBT. According to the guidelines of the American College of Gastroenterology, "Annual fecal immunochemical testing is the preferred colorectal cancer detection test." The FIT tests are clearly superior to traditional low sensitivity gFOBT for colorectal cancer screening. Although FIT has replaced most gFOBT tests in colon cancer screening, the high sensitivity gFOBT, such as Hemoccult SENSA, remains an accepted option although the FIT test is clearly preferred in recent guidelines. The number of fecal samples submitted for FIT may affect the clinical sensitivity and specificity of the methodology. This methodology can be adapted for automated test reading and to report quantitative results, which are potential factors in design of a widescale screening strategy. High-sensitivity FOBT may retain a role in monitoring gastrointestinal conditions such as ulcerative colitis. Stool guaiac test for fecal occult blood (gFOBT): The stool guaiac test involves smearing some feces on to some absorbent paper that has been treated with a chemical. Hydrogen peroxide is then dropped on to the paper; if trace amounts of blood are present, the paper will change color in one or two seconds. This method works as the heme component in hemoglobin has a peroxidase-like effect, rapidly breaking down hydrogen peroxide. In some settings such as gastric or proximal upper intestinal bleeding the guaiac method may be more sensitive than tests detecting globin because globin is broken down in the upper intestine to a greater extent than is heme. There are various commercially available gFOBT tests which have been categorized as being of low or high sensitivity, and only high sensitivity tests are now recommended in colon cancer screening. Optimal clinical performance of the stool guaiac test depends on preparatory dietary adjustment. Fecal porphyrin quantification: HemoQuant, unlike gFOBT and FIT, permits precise quantification of hemoglobin, and is analytically validated with gastric juice and urine, as well as stool samples. The heme moiety of intact hemoglobin is chemically converted by oxalic acid and ferrous oxalate or ferrous sulfate to protoporphyrin, and the porphyrin content of both the original sample and of the sample after hemoglobin conversion to porphyrin is quantified by comparative fluorescence against a reference standard; the specificity for hemoglobin is increased by subtracting the fluorescence of a sample blank prepared with citric acid to correct for the potential confounding effect of existing non-specific substances. Precise quantification measurement has been very useful in many clinical research applications. Fecal DNA test: The test extracts human DNA from the stool sample and tests it for alterations that have been associated with cancer. The test looks at 23 individual DNA alterations, including 21 specific point alterations in the APC, KRAS and p53 genes, as well as testing BAT26, a gene involved in microsatellite instability (MSI). and a proprietary DNA Integrity Assay (DIA). Additional methods of looking for occult blood are being explored, including transferrin dipstick and stool cytology.

Test performance: Reference standards: The estimates for test performance characteristics are based on comparison with a variety of reference methods including 51-chromium studies, analytical recovery studies in spiked stool samples, analytical recovery after ingestion of autologous blood, rarer studies of carefully quantified blood instilled at bowel surgery as well as other research approaches. Additionally, clinical studies look at variety of additional factors.

Gastrointestinal blood loss in health: In healthy people about 0.5 to 1.5 ml of blood escapes blood vessels into the stool each day. Significant amounts of blood can be lost without producing visible blood in the stool, estimated as 200 ml in the stomach, 100 ml in the duodenum, and lesser amounts in the lower intestine. Tests for occult blood identify lesser blood loss.

Clinical sensitivity and specificity: Stool guaiac test for fecal occult blood (gFOBT) sensitivity varies depending on the site of bleeding. Moderately sensitive gFOBT can pick up a daily blood loss of about 10 ml (about two teaspoonfuls), and higher sensitivity gFOBT can pick up lesser amounts, sometimes becoming positive at about 2 ml. The sensitivity of a single stool guaiac test to pick up bleeding has been quoted at 10 to 30%, but if a standard three tests are done as recommended the sensitivity rises to 92%. Further discussion of sensitivity and specificity issues that relate particularly to the guaiac method is found in the stool guaiac test article. Fecal Immunochemical Testing (FIT) picks up as little as 0.3 ml but because it does not detect occult blood from the stomach and upper small intestine the test threshold doesn't cause undue false positives from normal upper intestinal blood leakage and it is much more specific for bleeding from the colon or lower gastrointestinal tract. The detection rate of the test decreases if the time from sample collection to laboratory processing is delayed. Fecal porphyrin quantification by HemoQuant can be false positive due to exogenous blood and various porphyrins. HemoQuant is the most sensitive test for upper gastrointestinal bleeding and therefore may be most appropriate fecal occult blood test to use in the evaluation of iron deficiency Advised to stop red meat and aspirin for 3 days prior to specimen collection. False positives can occur with myoglobin, catalase, or protohemes and in certain types of porphyria. The DNA based PreGen-Plus was four times more sensitive than fecal blood testing, including detection of early stage disease, when treatment is most effective. Sensitivity increased to 51.6% compared to 12.9%. Additional clinical trials of the PreGen-Plus method are underway to more fully characterize its clinical performance. Expanding the range of DNA testing by looking at additional known genetic markers, such as CTNNB1, or by analyzing epigenetically methylated genes such as MLH1 which is very common in serrated polyps with microsatellite instability (MSI) and in proximal colon tumours that have poorer differentiation, does not appear to appreciably increase the sensitivity of the method because CTNNB1 mutations are infrequent in sporadic colorectal cancer, and because BAT26 alterations and lack of MLH1 expression show a high degree of overlap.

(*To be continued*)

TULIP NEWS

HEMOSTAR XF 2.0

2 Channel Haemostasis Analyzer

EQUIPPED FOR TODAY

- Measurement : Opto - mechanical measuring system
- Assays modes : PT/APTT/TT/FIB/ FACTORS/ PC/PS/other clot based assays
- Display : Large, backlit, graphical LCD
- Calibration : 2 - 7 Pt. with plot
- Incubation : 2 reagent, 16 specimen and 2 reading positions at 37 ± 1°C
- Reporting : Seconds, Ratio, % A, INR, mg/dl, g/L, IU/ml
- Printer : Inbuilt thermal

In Synergy with India's widely used PT reagents UNIPLASTIN and LIQUIPLASTIN for uniformity in INR

Xtra Features

READY FOR TOMORROW

- 2 Channels with independent optics
- Random assay testing
- 50 Programmable assay locations
- Sample ID upto 10 numeric characters
- 3 - Level QC
- Levey Jennings plot
- Data transfer- RS 232

Dominate The Future

In Haemostasis Assessment

Printed and published by D.G. Tripathi, Edited by Dr. Ramnik Sood, M.D. (Path.) for and on behalf of Tulip Diagnostics Private Ltd., Gitanjali, Tulip Block, Dr. Antonio Do Rego Bagh, Alto Santacruz, Bambolim Complex Post Office, Goa - 403 202, INDIA.
Fax: (0832) 2458544. E-mail: sales@tulipgroup.com Website: www.tulipgroup.com